

Scotland and Northern Ireland EQA Scheme

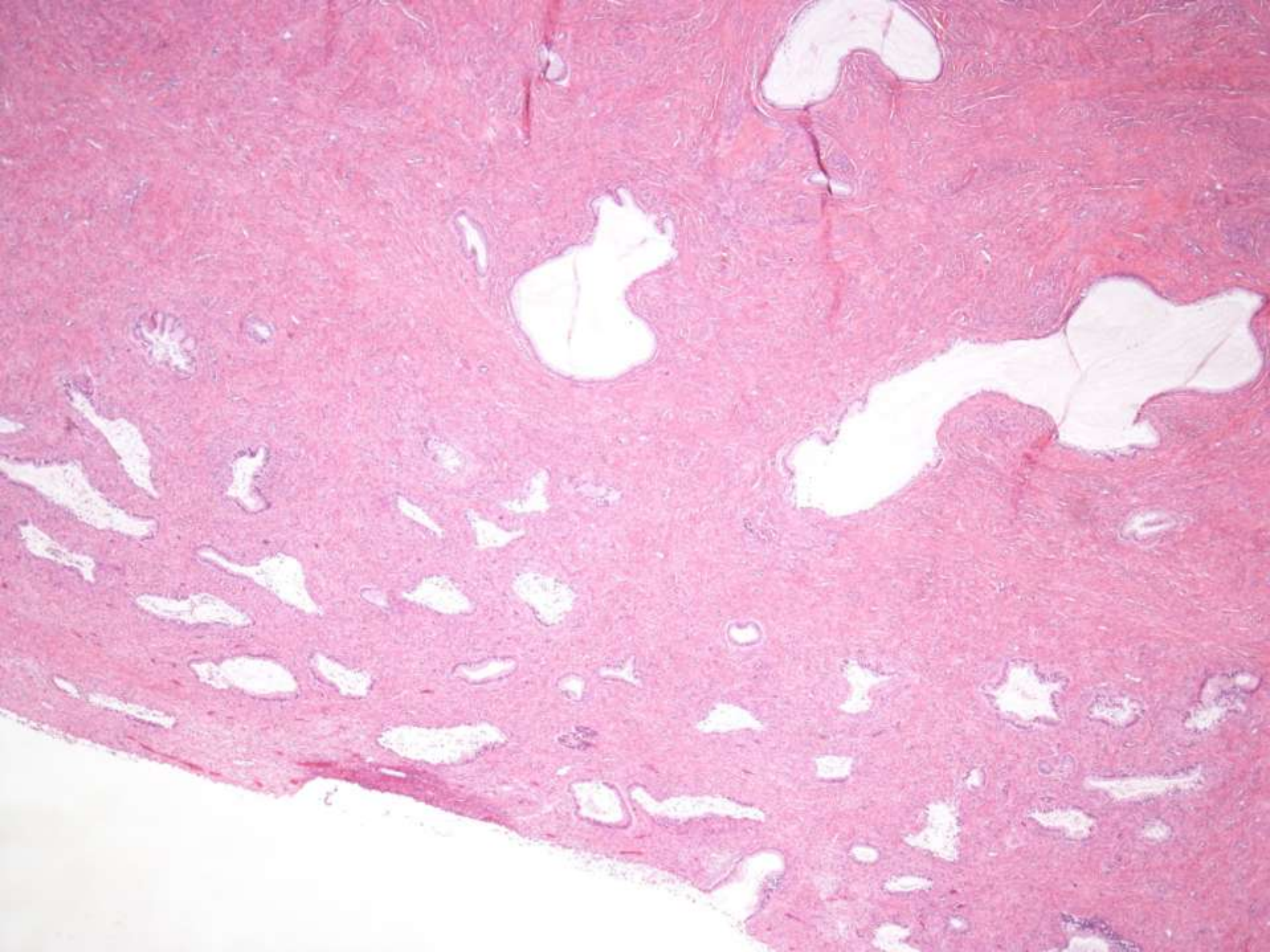
Circulation 48

Cases A to E

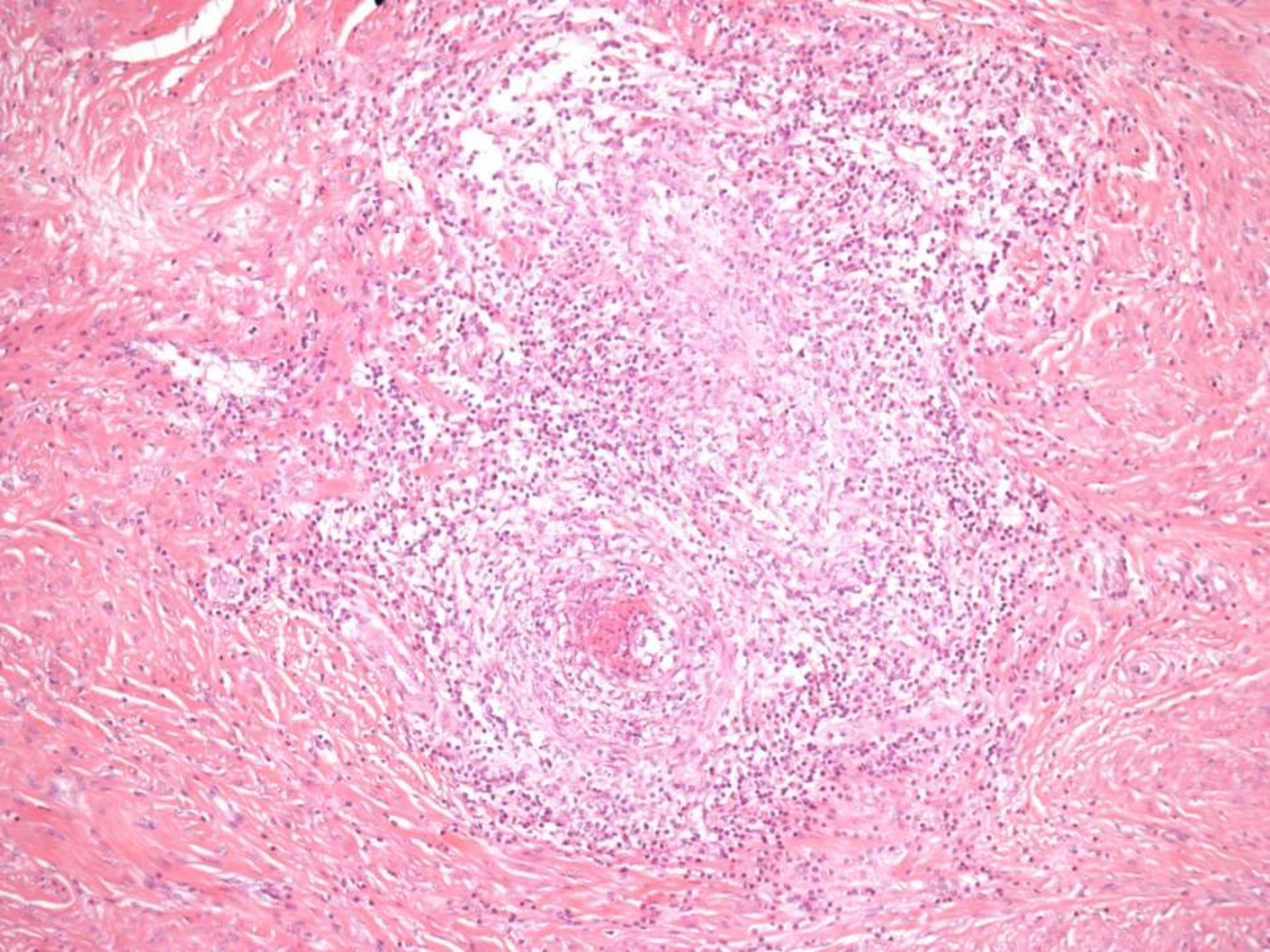
Submitted by Dr M Brown

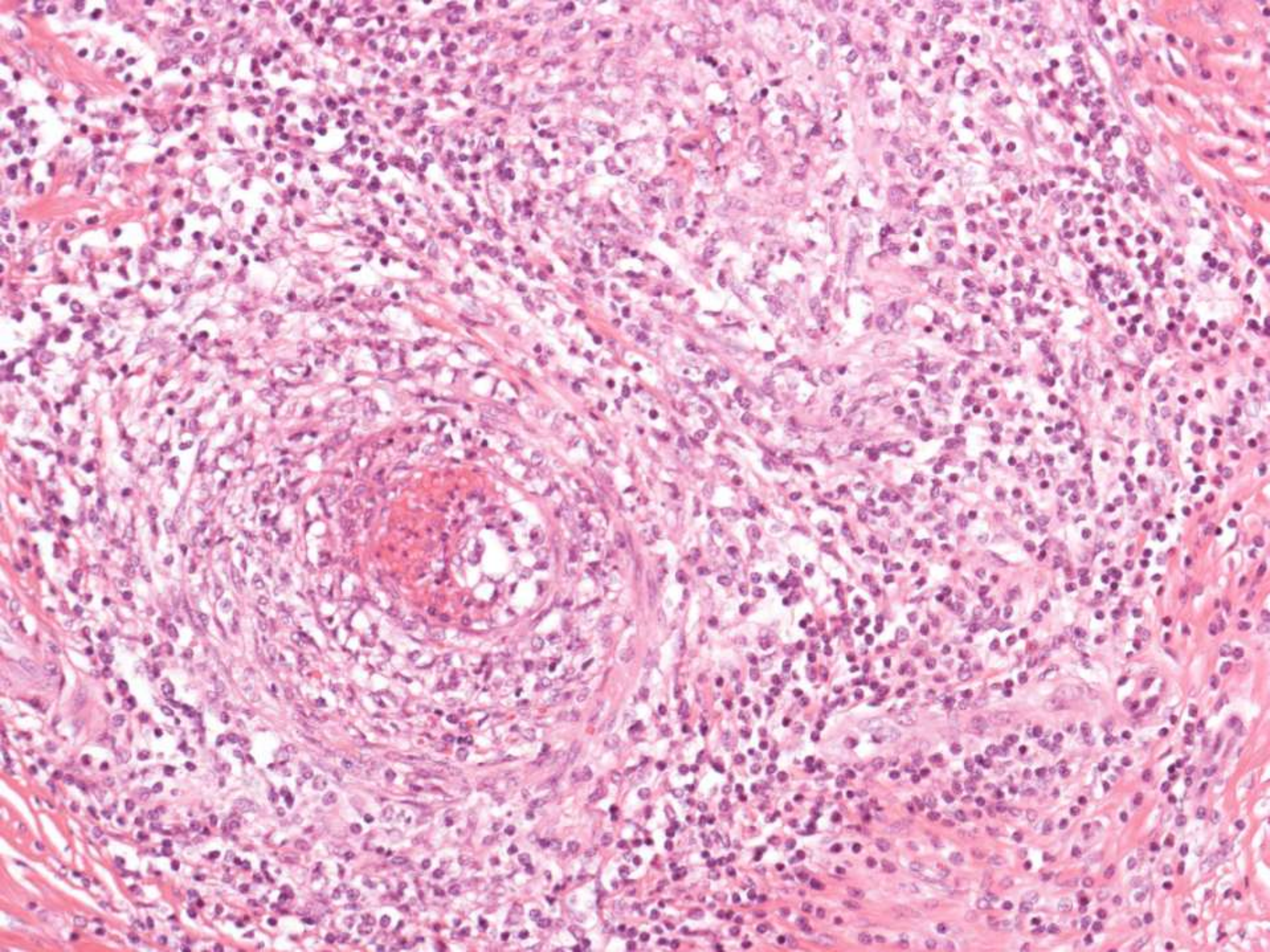
Case A

- 49 year old female
 - Menorrhagia- on Norethisterone
 - Hysterectomy
 - Block from cervix









Case A

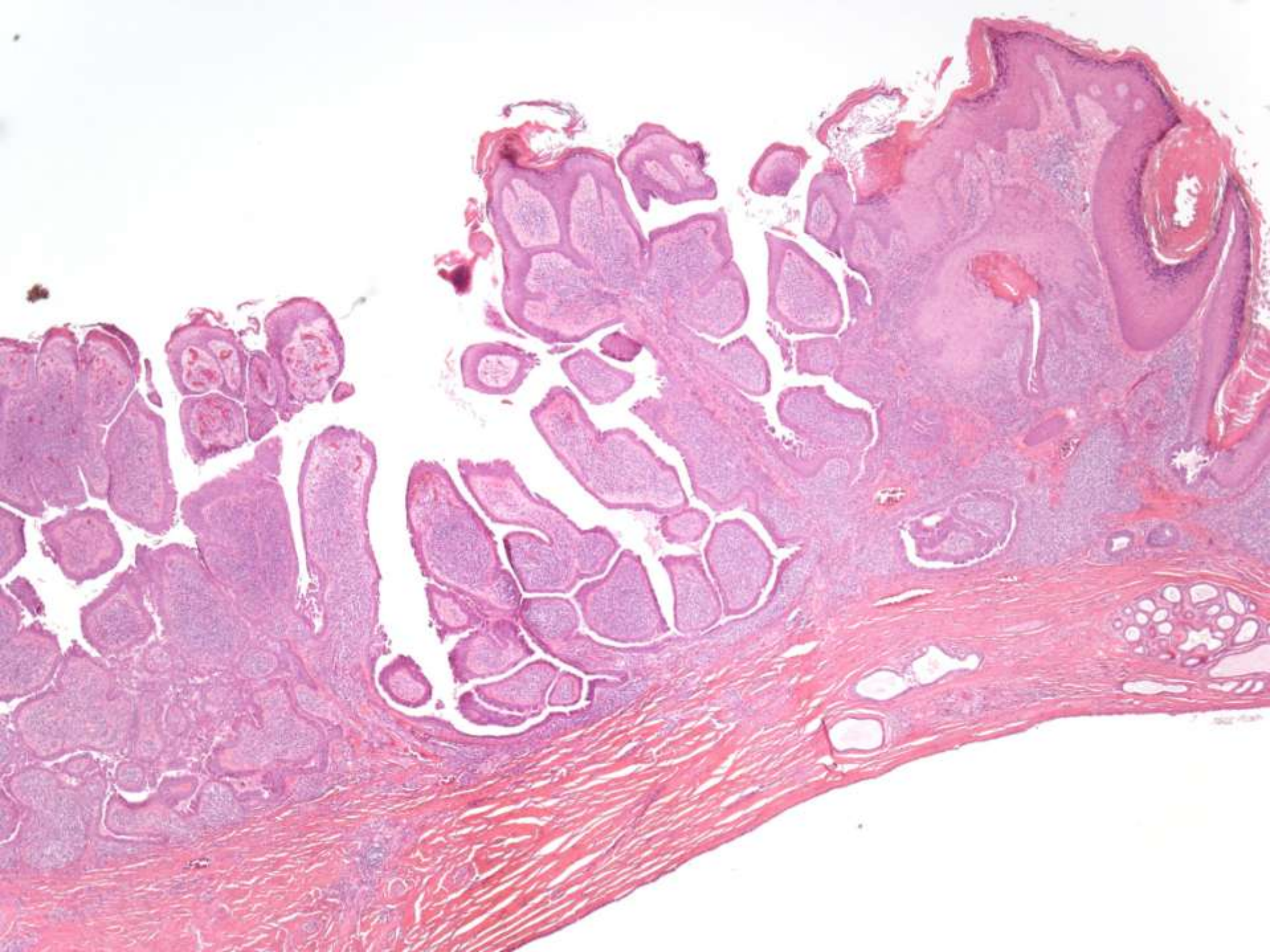
- Diagnosis:
 - Vasculitis

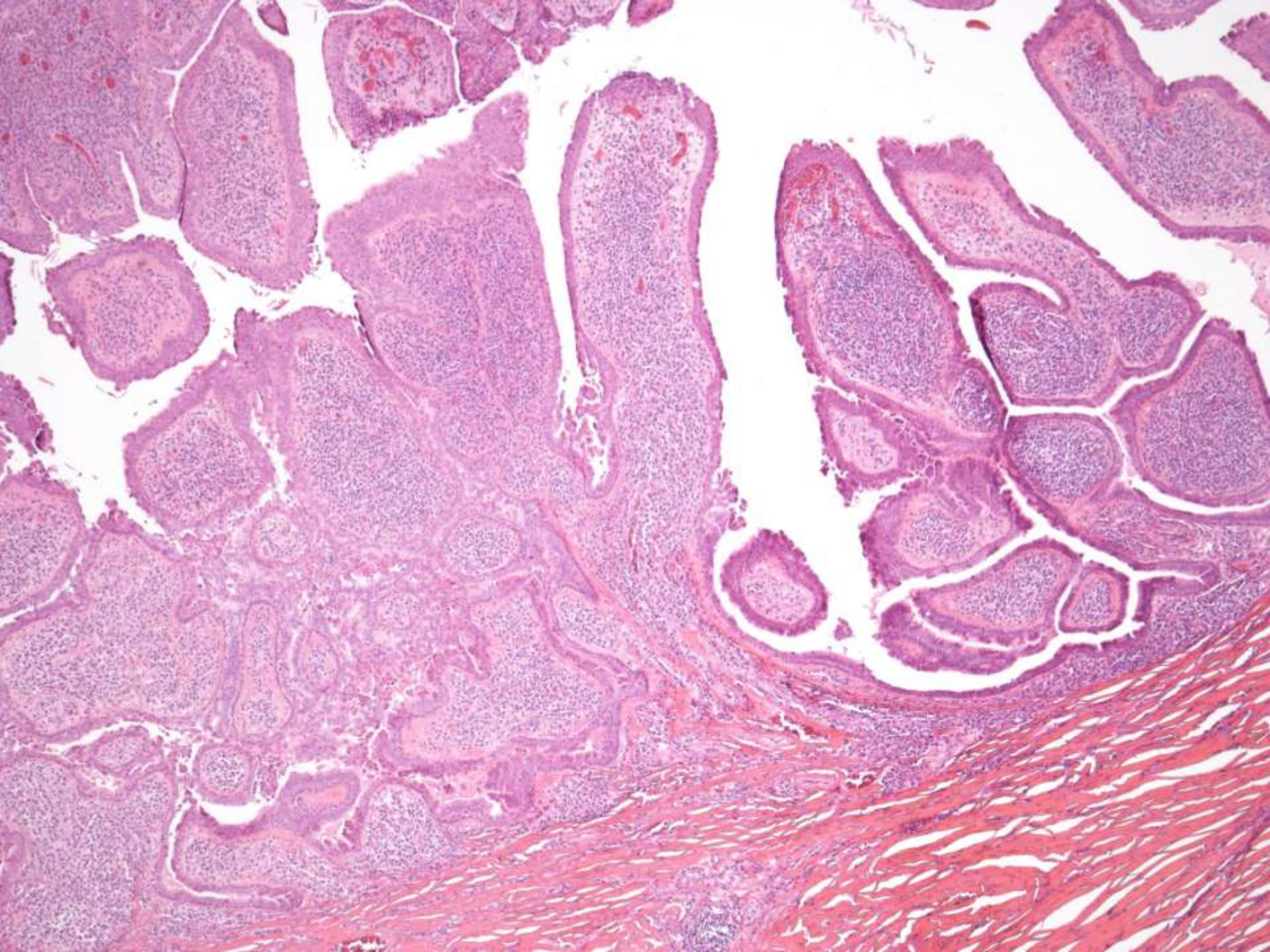
Case A

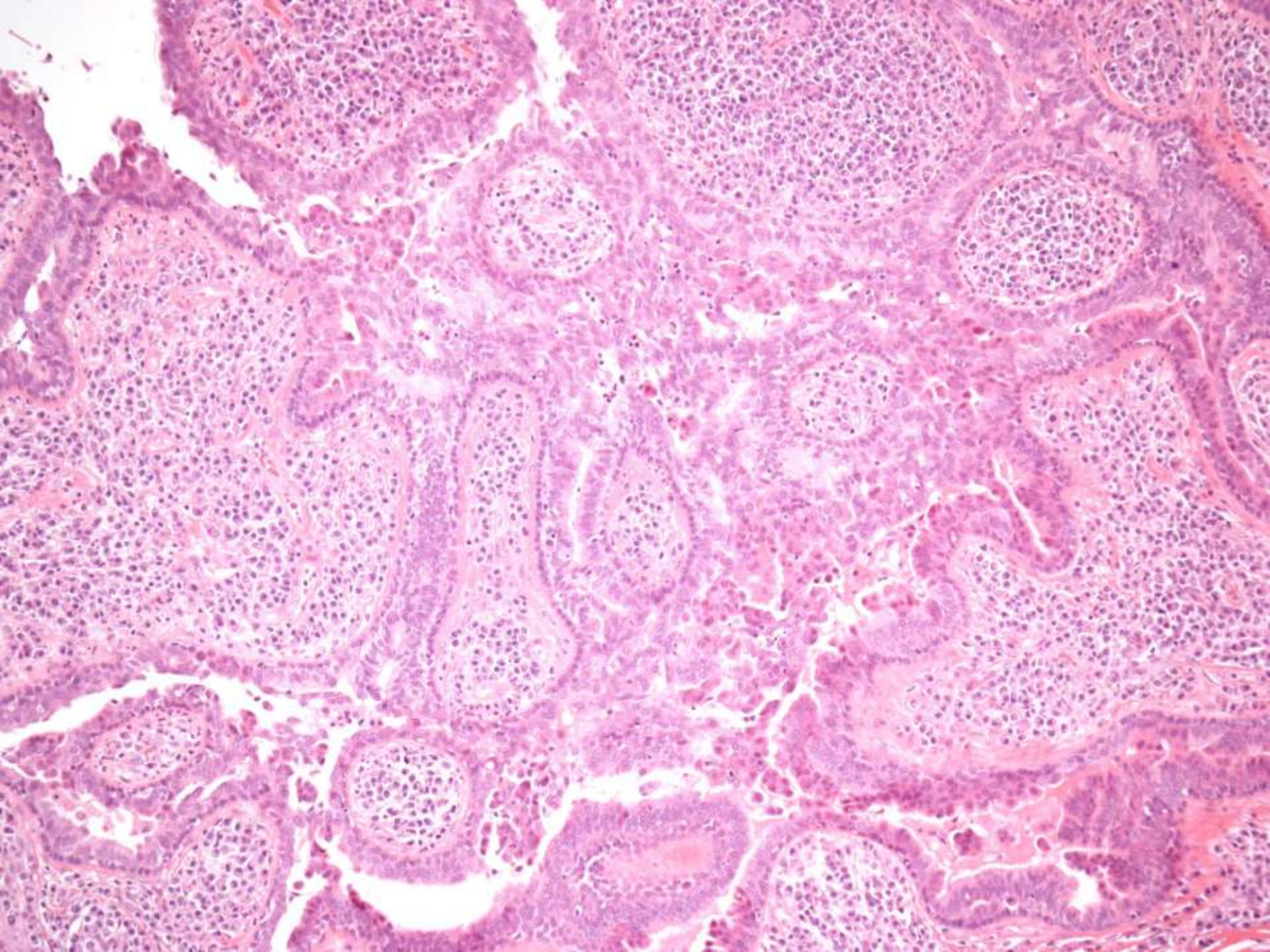
- Responses:
 - Score 1
 - 114 - Vasculitis
 - Score 3
 - 1 - Endometriosis

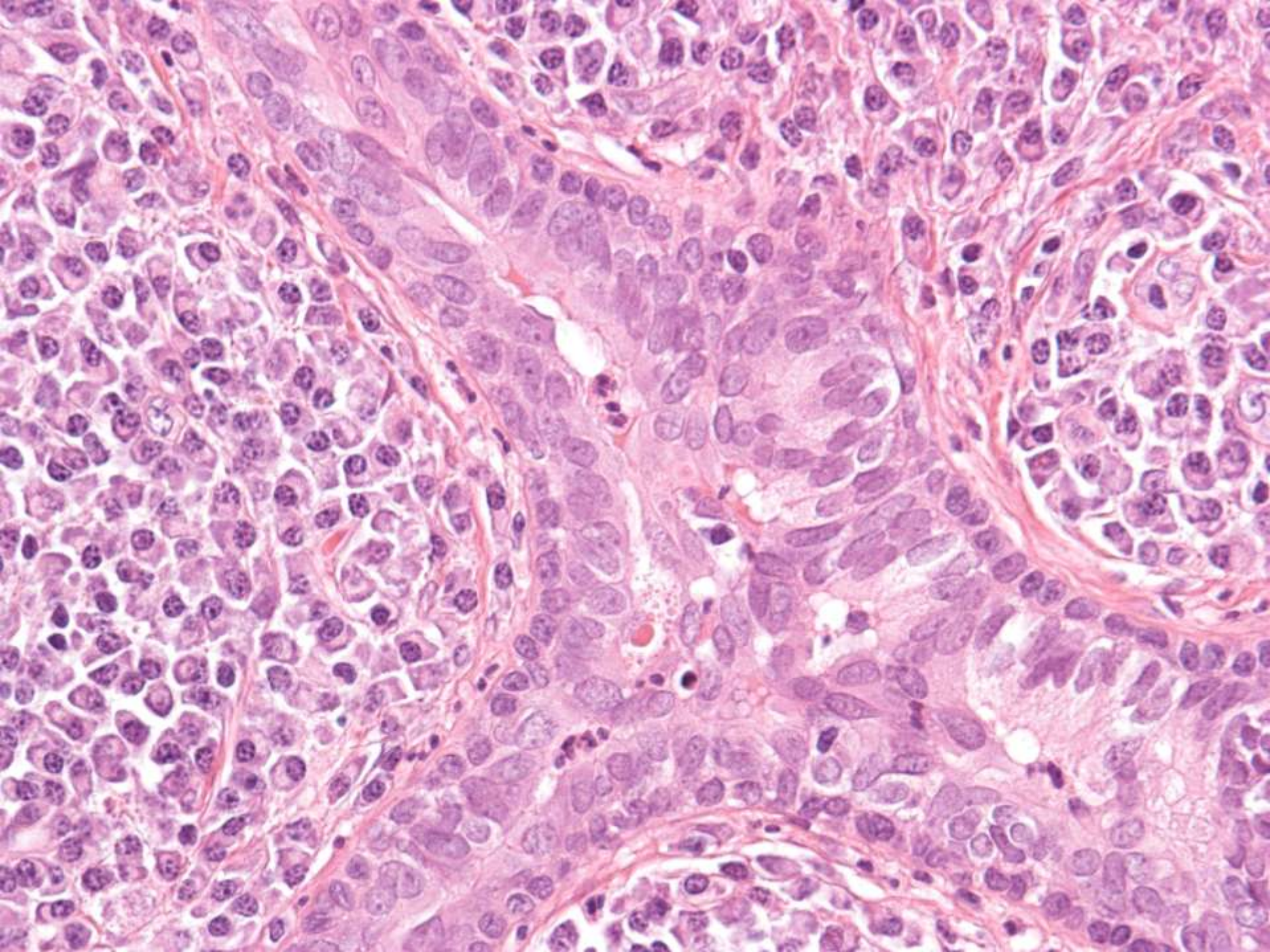
Case B

- 70 year old male
 - Scalp lesion ?SCC









Case B

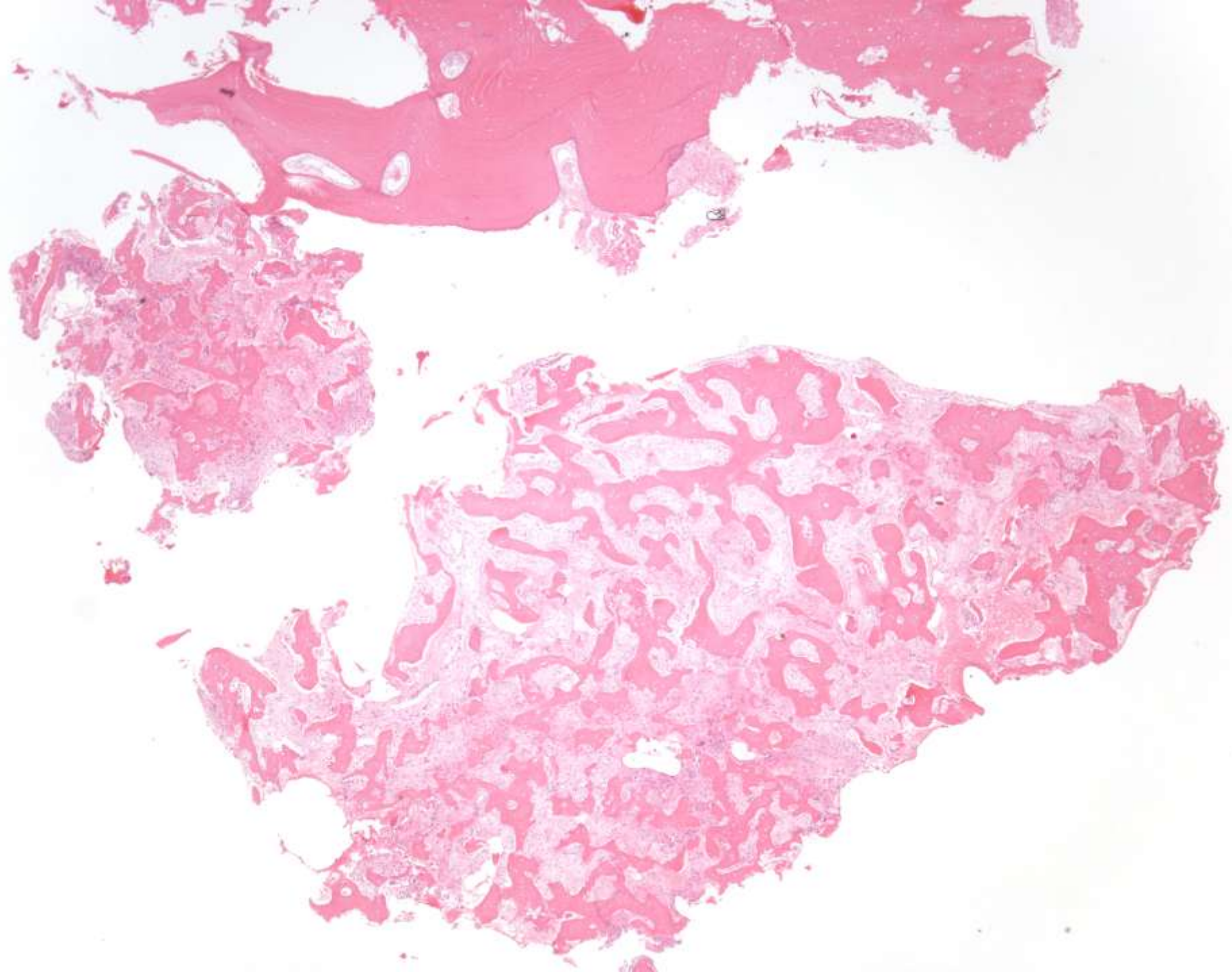
- Diagnosis:
 - Syringocystadenoma papilliferum

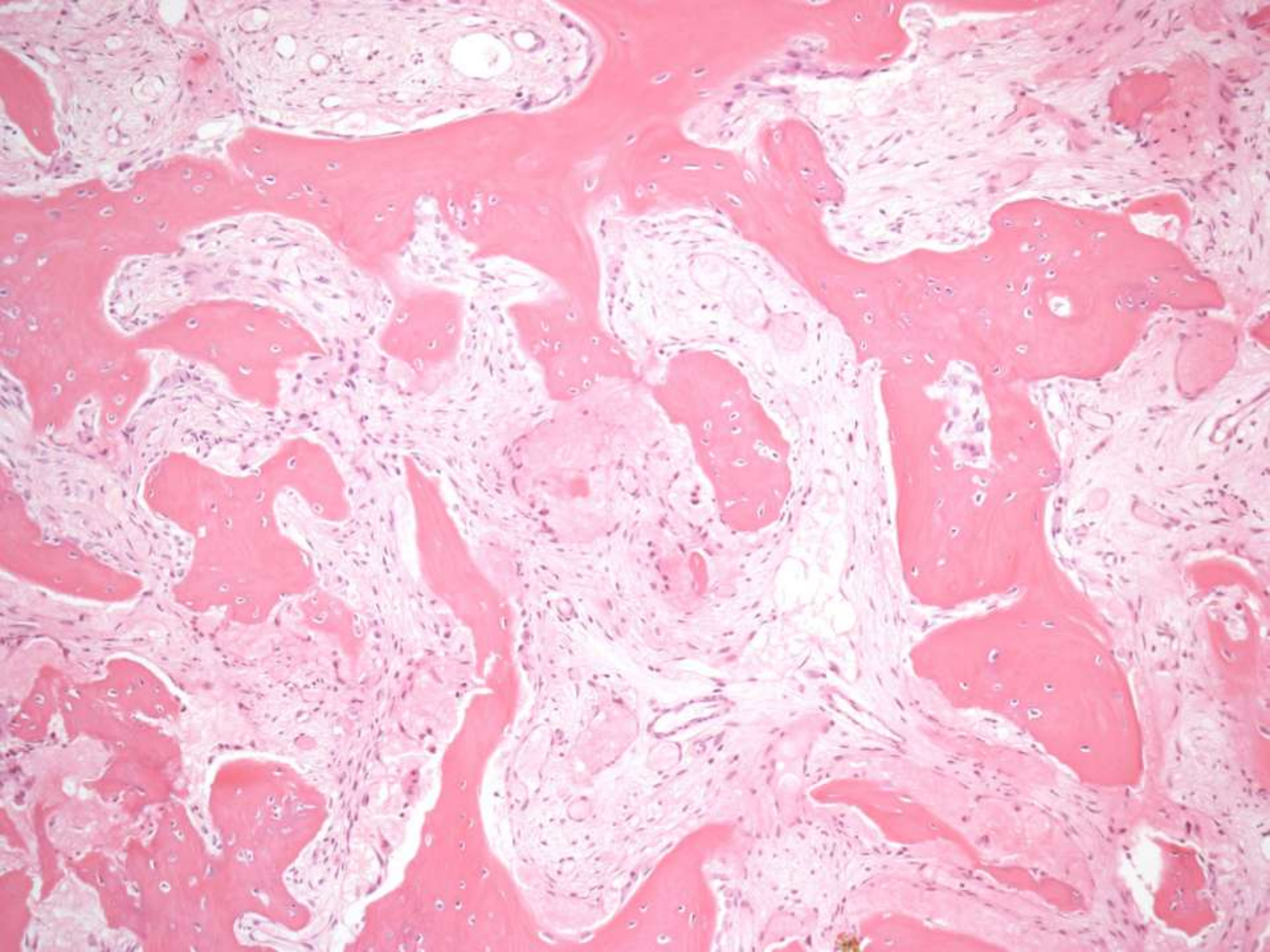
Case B

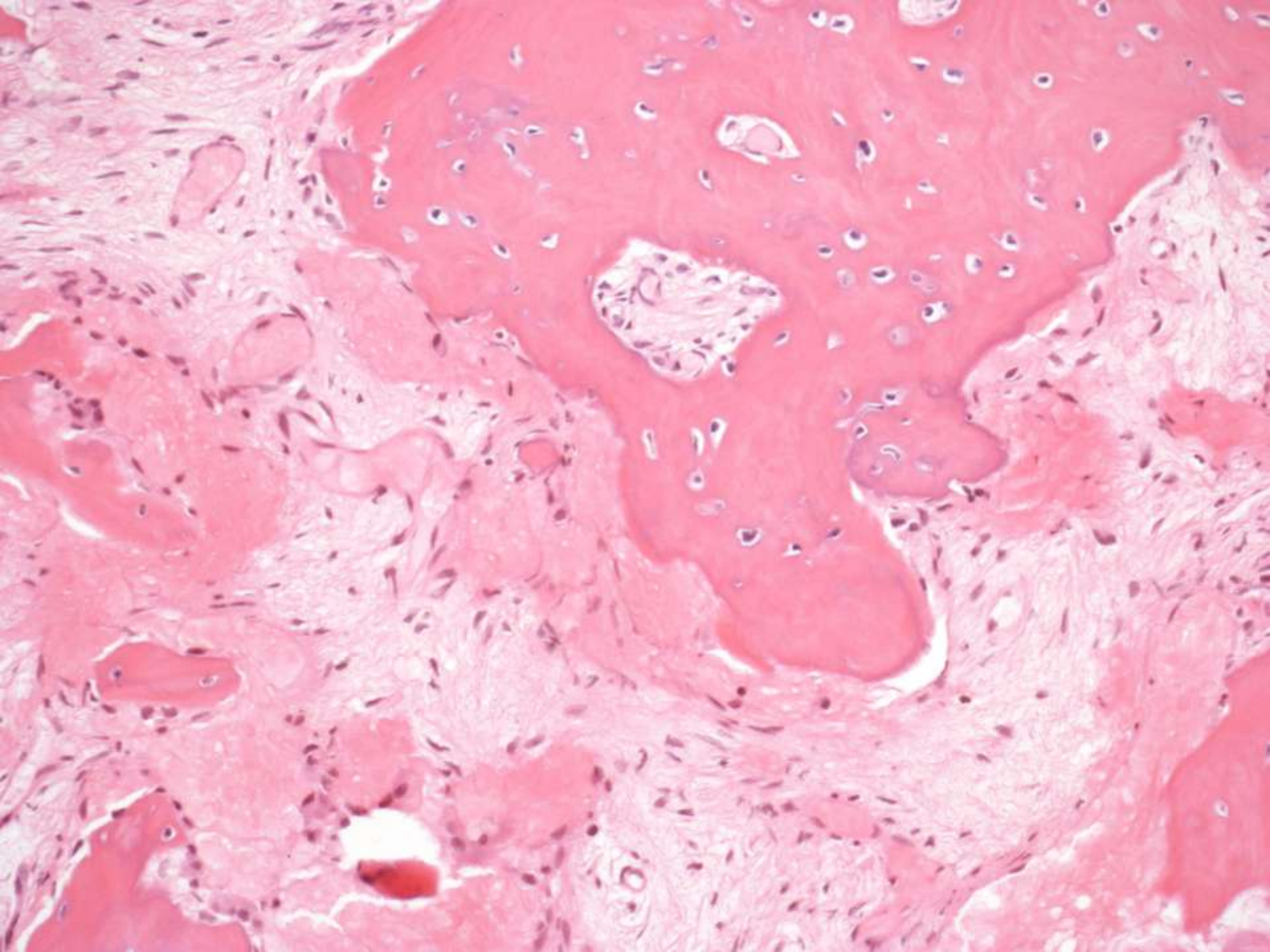
- Responses:
 - Score 1
 - 115 – Syringocystadenoma papilliferum

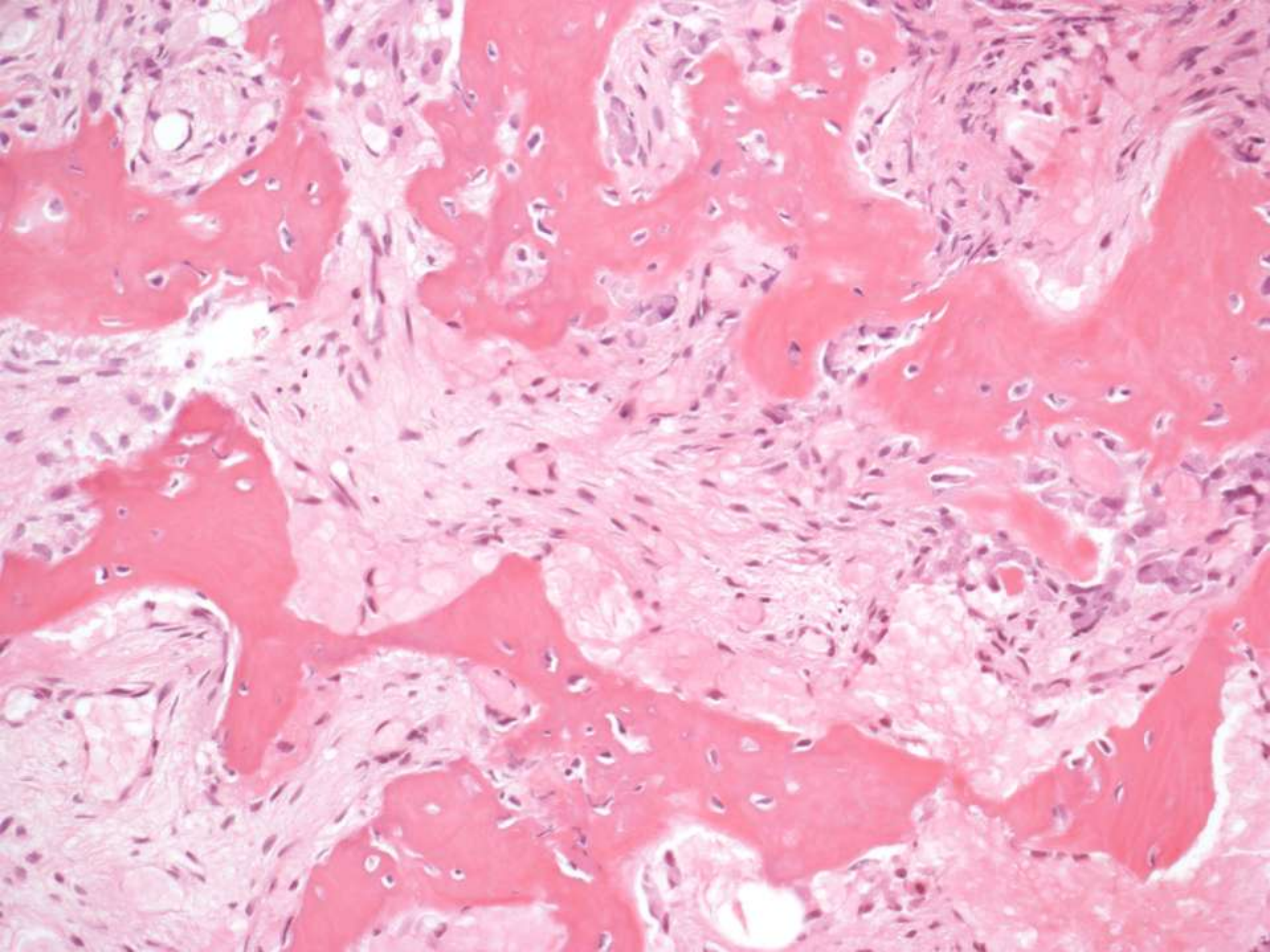
Case C

- 26 year old male
 - Pain lower left mandible ?fibrous dysplasia









Case C

- Diagnosis:
 - Fibrous dysplasia

Case C

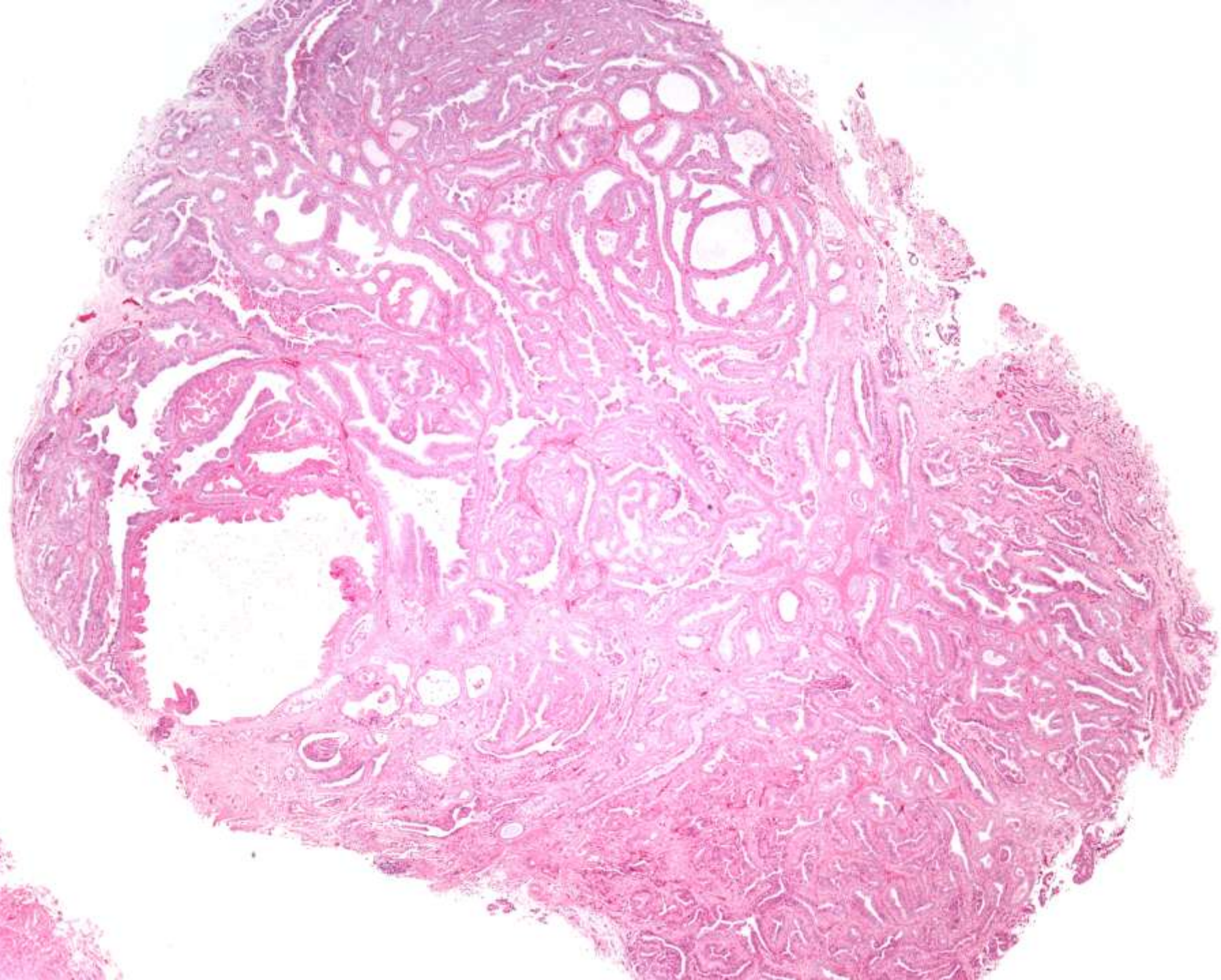
- Responses:
 - Score 1
 - 104 - Fibrous dysplasia
 - 3 - Ossifying fibroma
 - 1 - Fibro-osseous lesion such as fibrous dysplasia
 - 1 - Fibrous dysplasia / ossifying fibroma
 - 1 - DDx Fibro-osseous lesion of jaw / osteoid osteoma / ossifying fibroma
 - 1 - Ossifying fibroma with differential diagnosis of fibro-osseous lesion

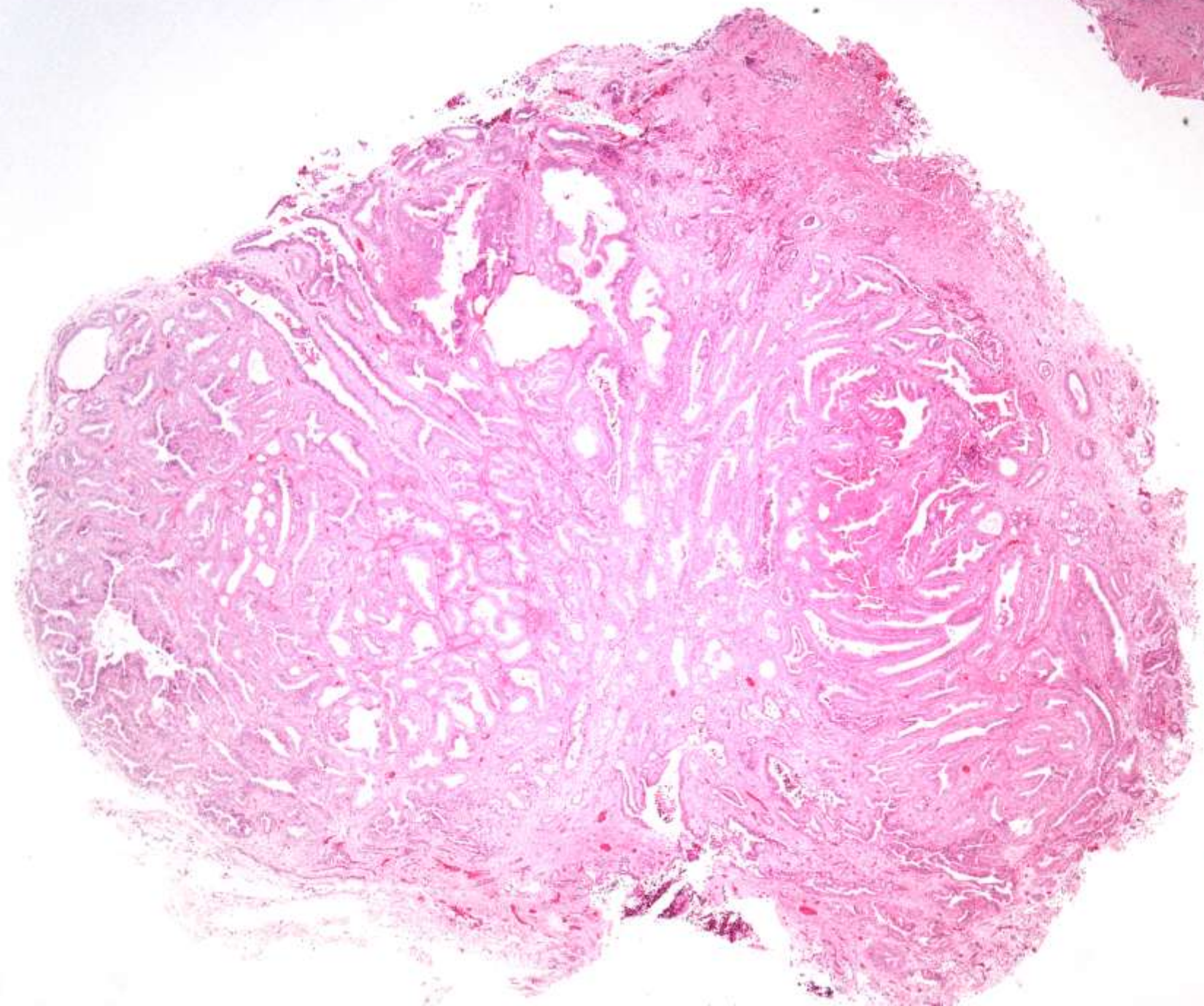
Case C

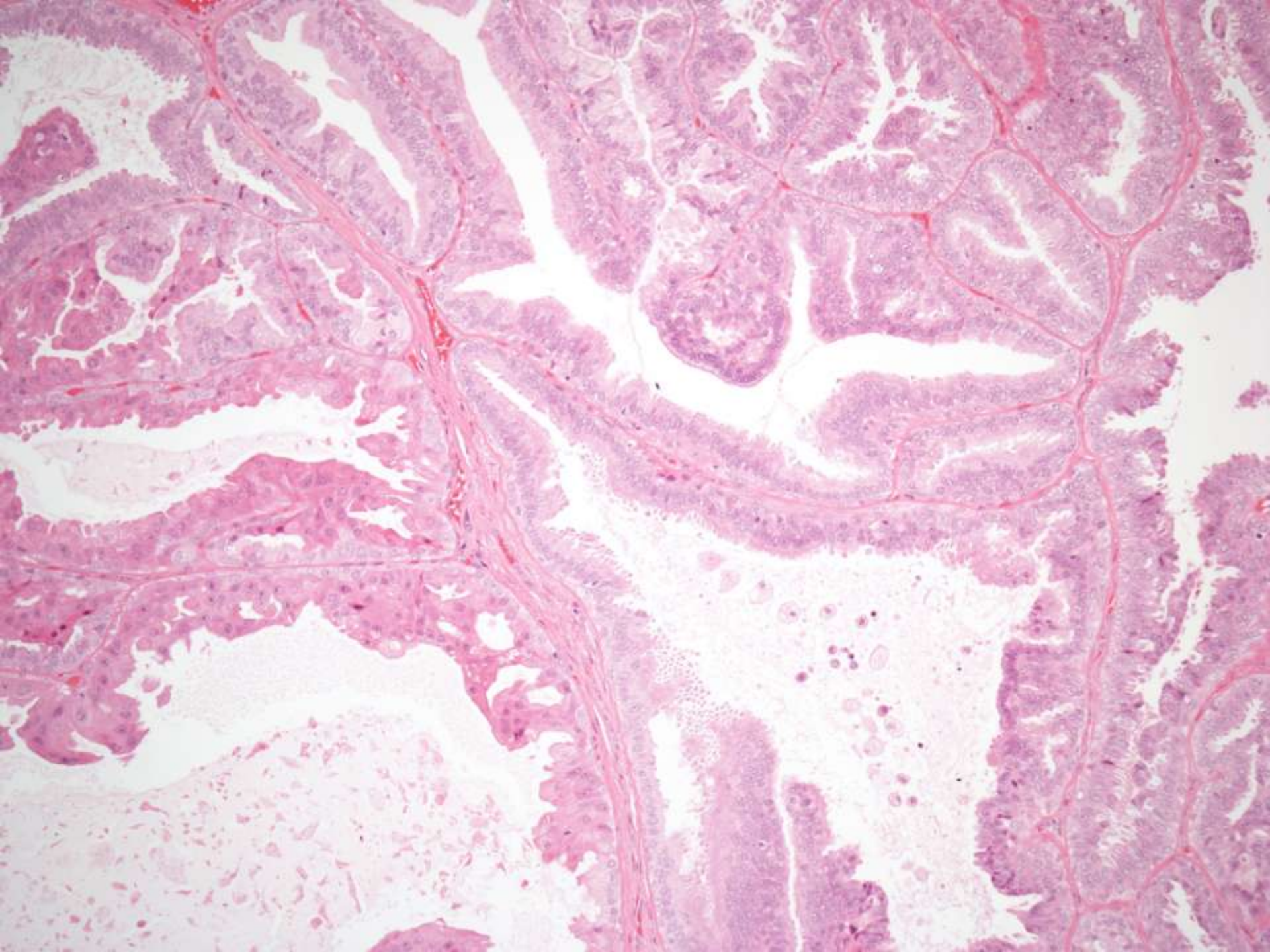
- Responses:
 - Score 2
 - 2 - Osteoid osteoma
 - 1- Paget's
 - 1 - DDx well differentiated osteosarcoma vs fibrous dysplasia

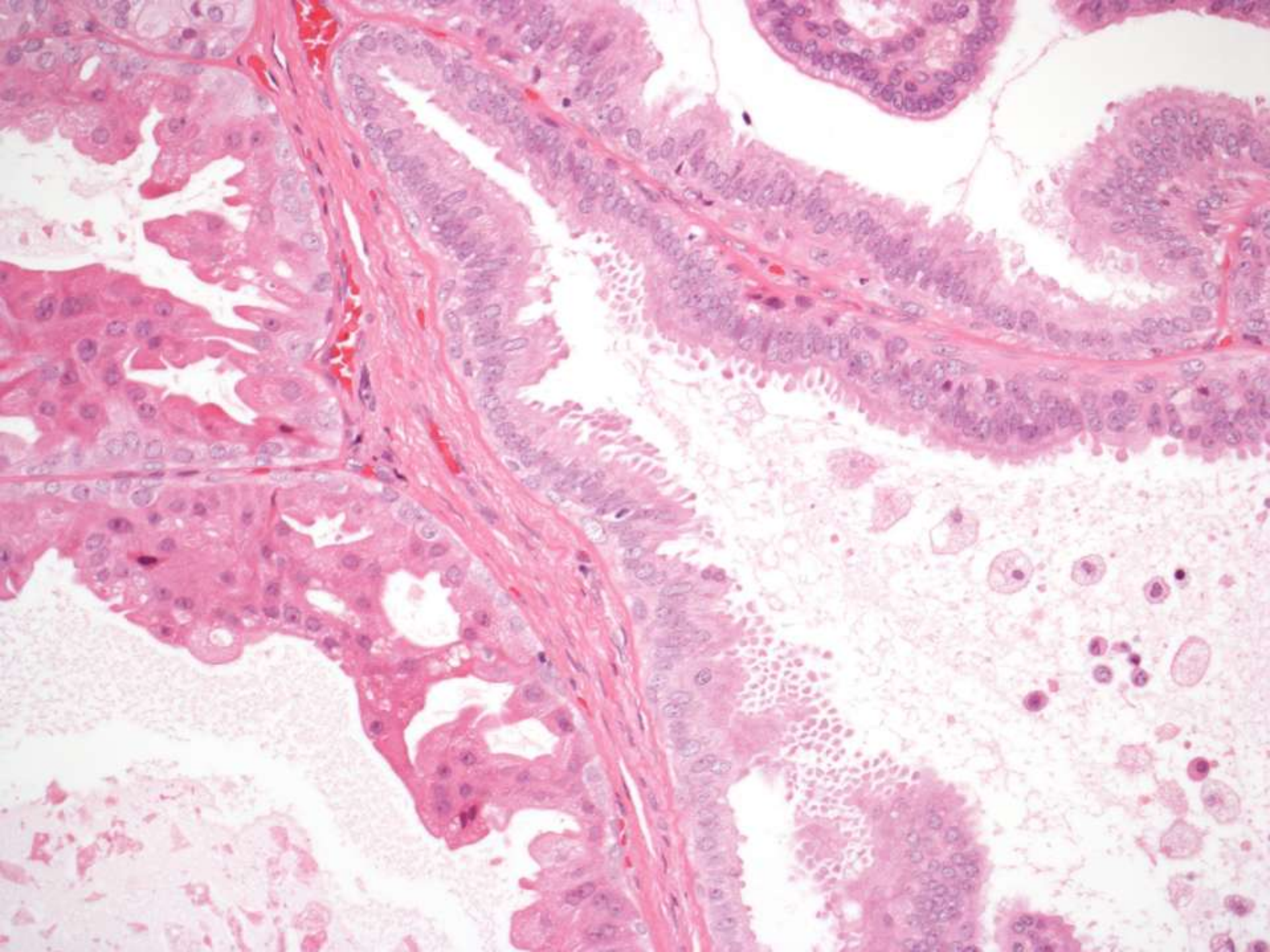
Case D

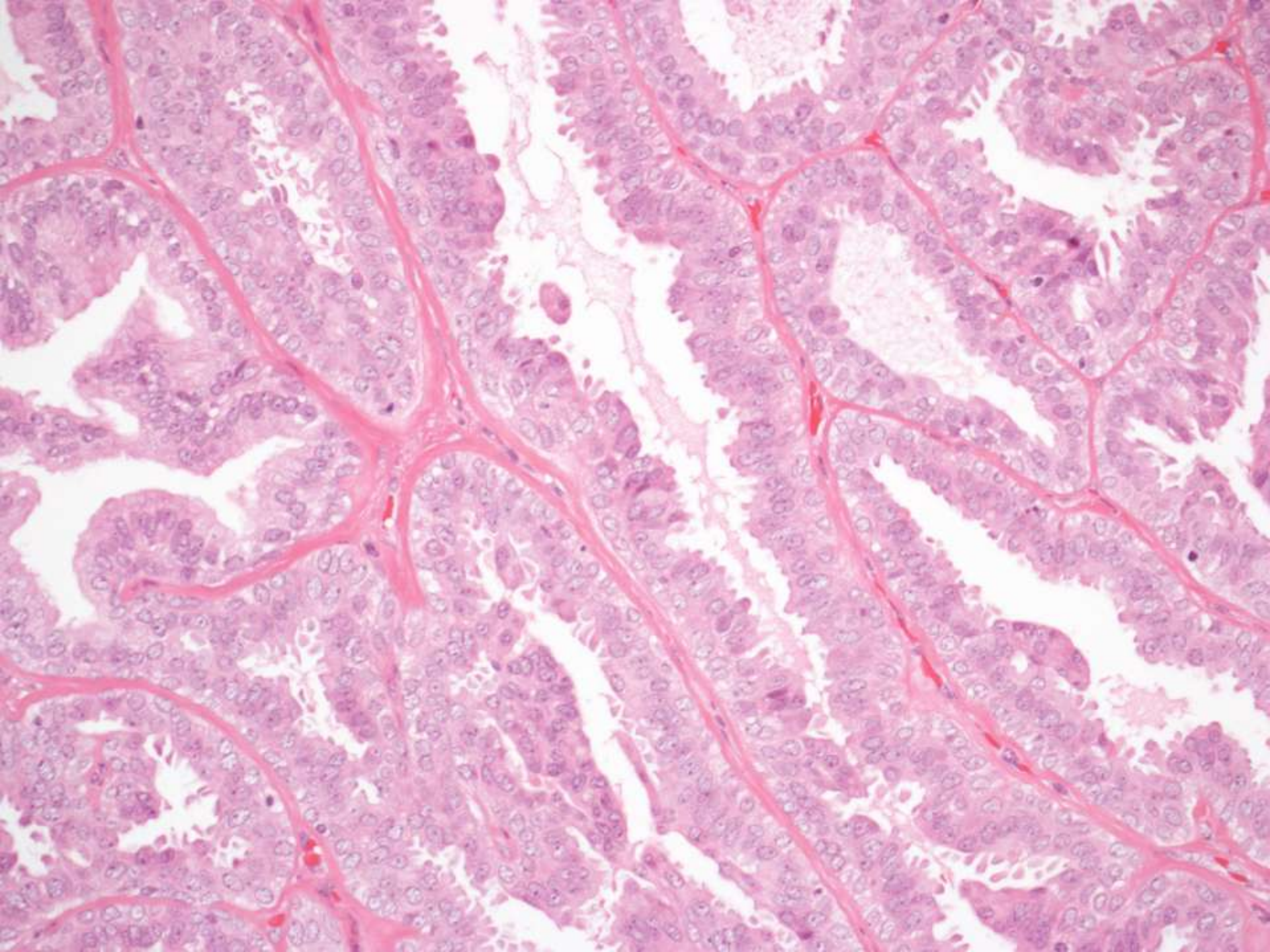
- 57 year old female
 - Superficial lump in vulva ?lipoma











Case D

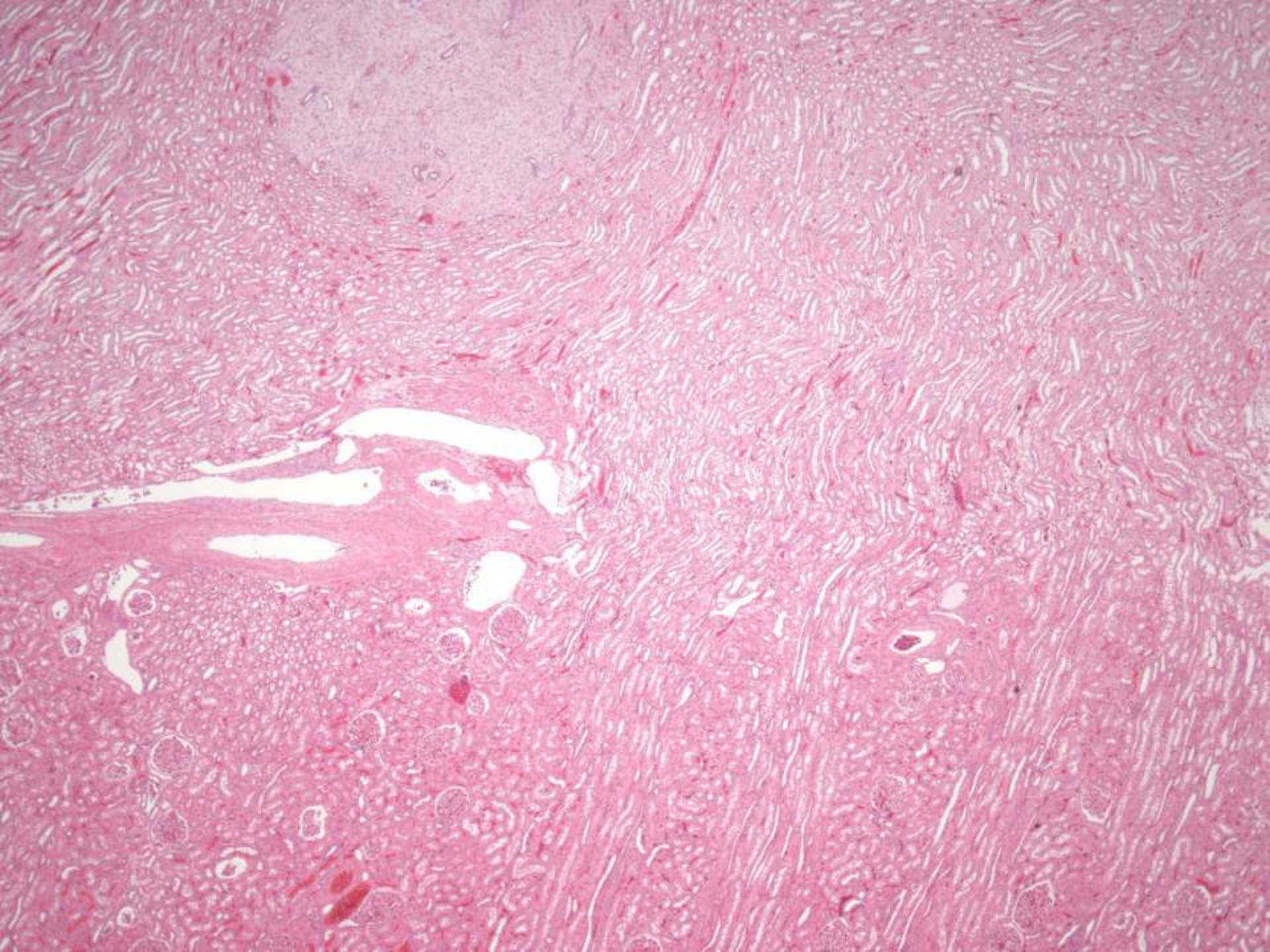
- Diagnosis:
 - Hidradenoma papilliferum

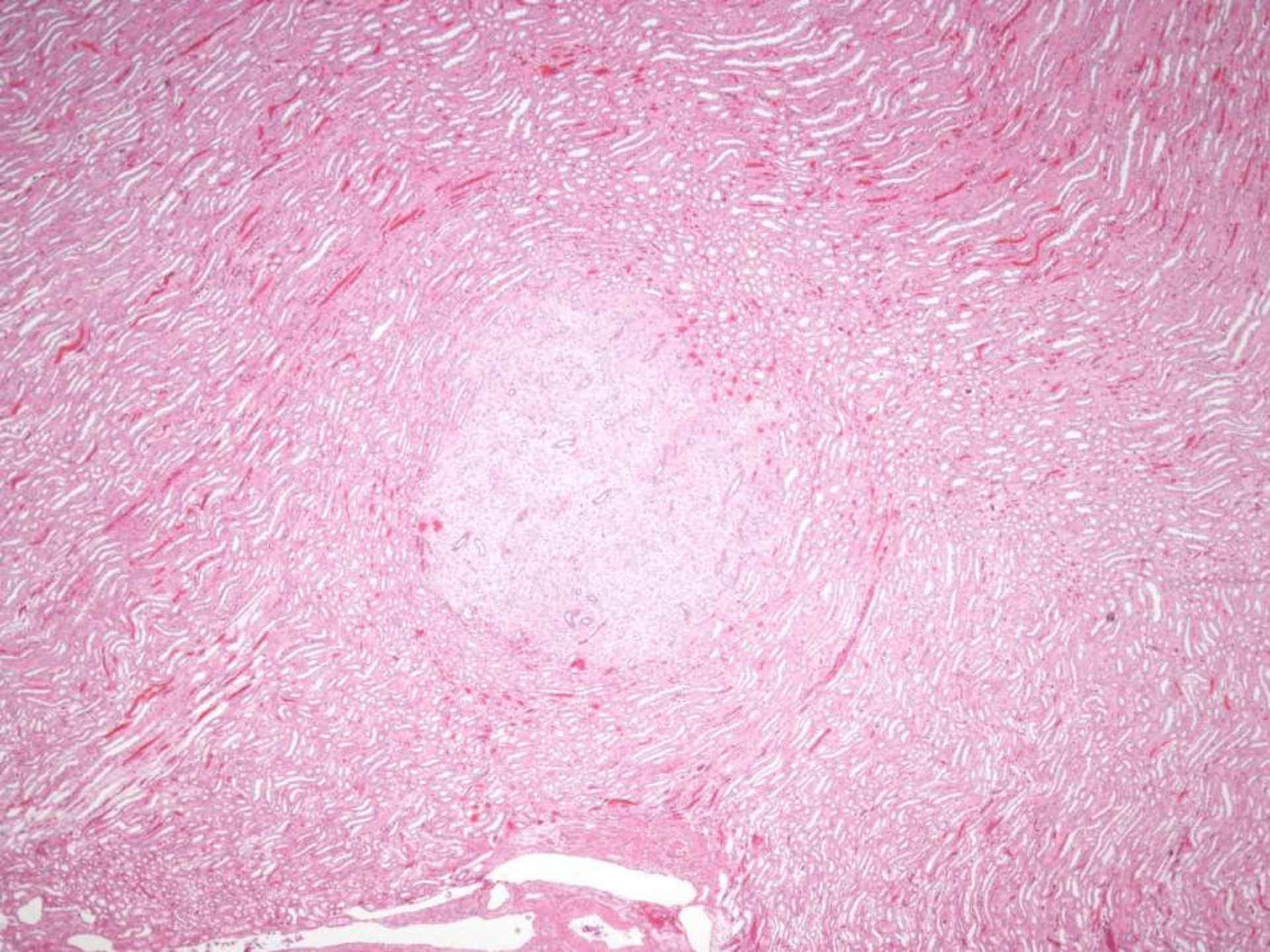
Case D

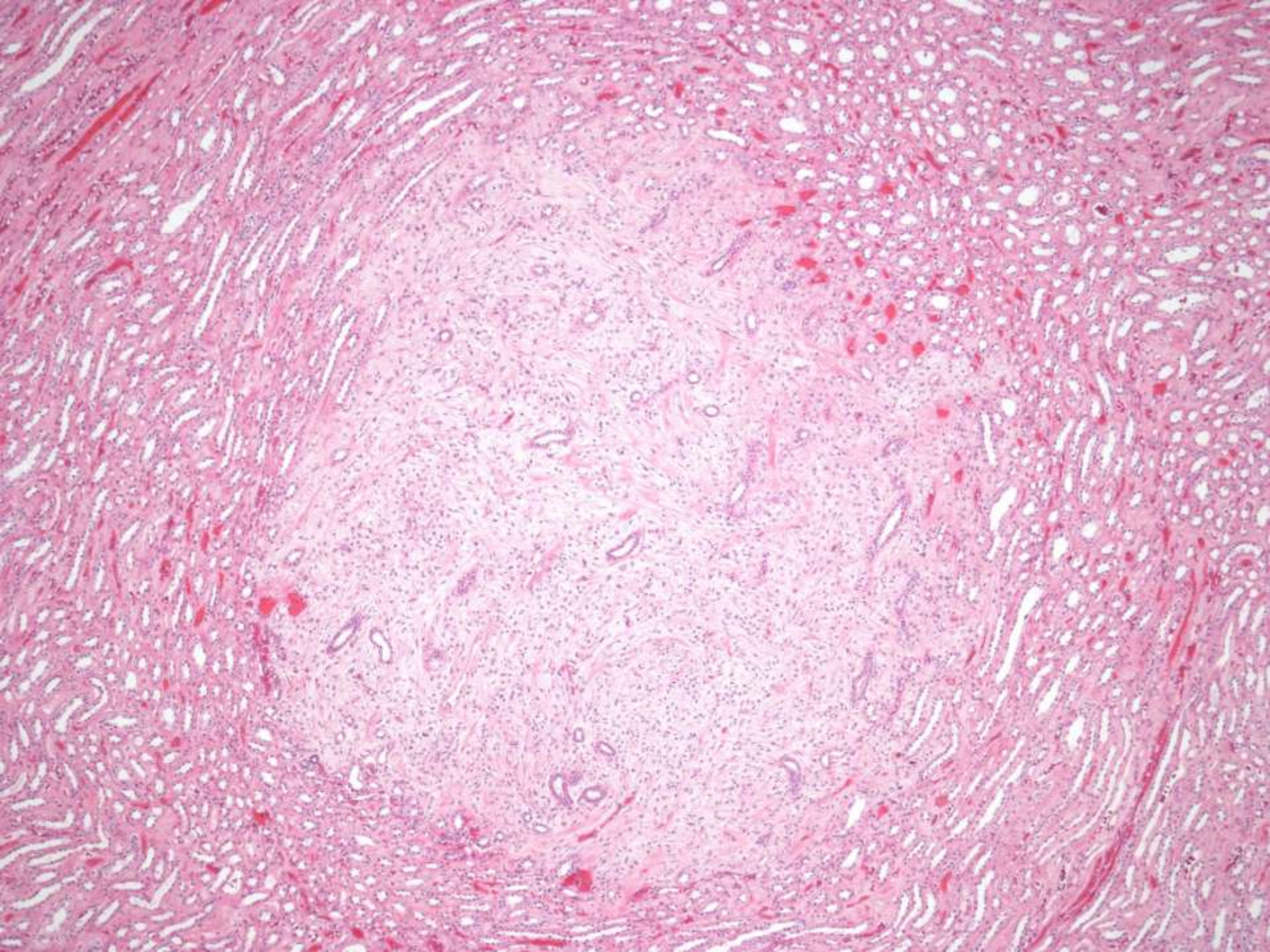
- Responses:
 - Score 1
 - 110 - Hidradenoma papilliferum
 - Score 2
 - 1- Apocrine adenoma with DDx of syringocystadenoma papilliferum
 - 1- Apocrine hidradenoma
 - 1 - Benign adnexal tumour / apocrine adenoma
 - 1 - Apocrine cystadenoma
 - 1 - Ectopic breast tissue

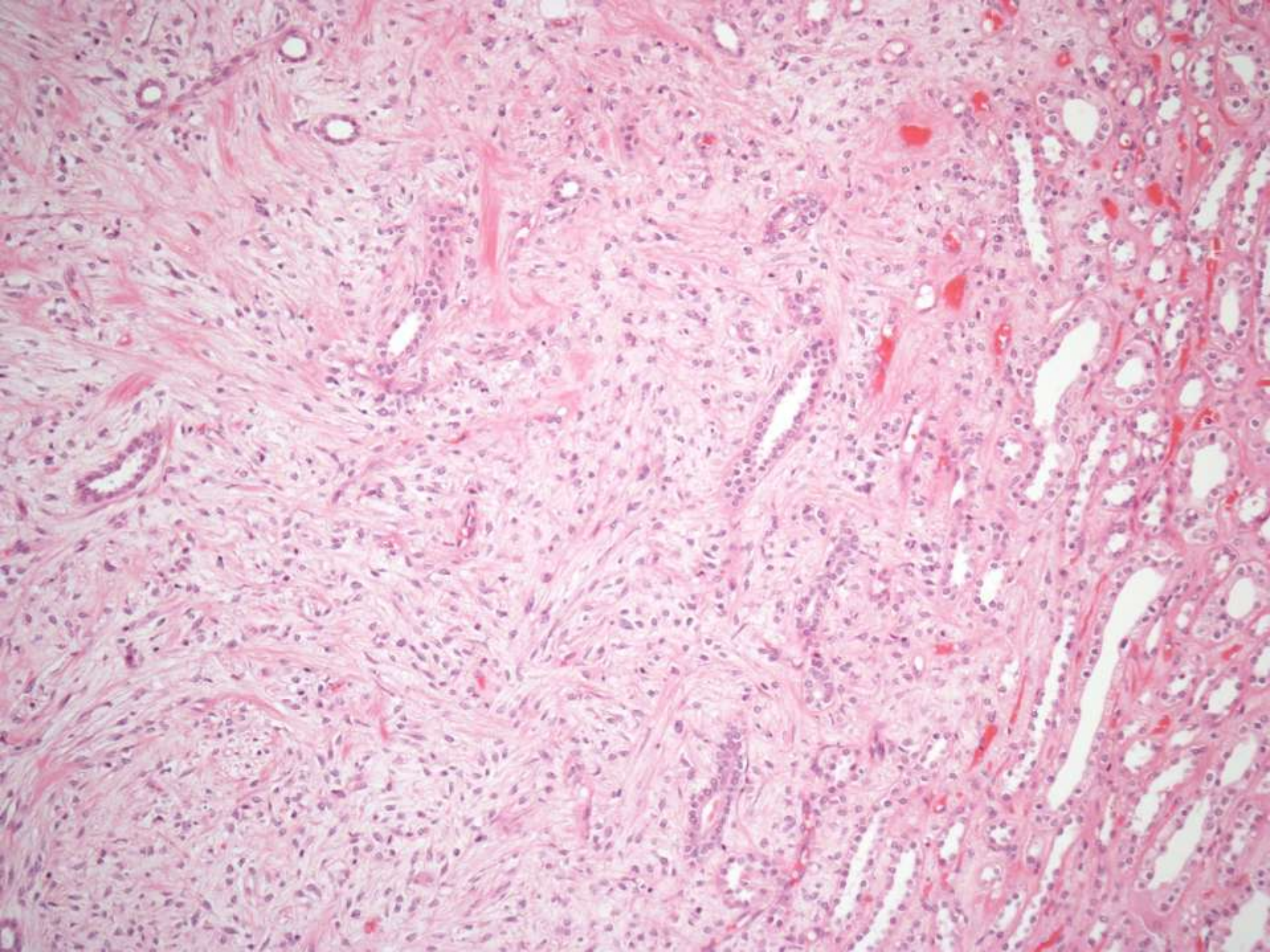
Case E

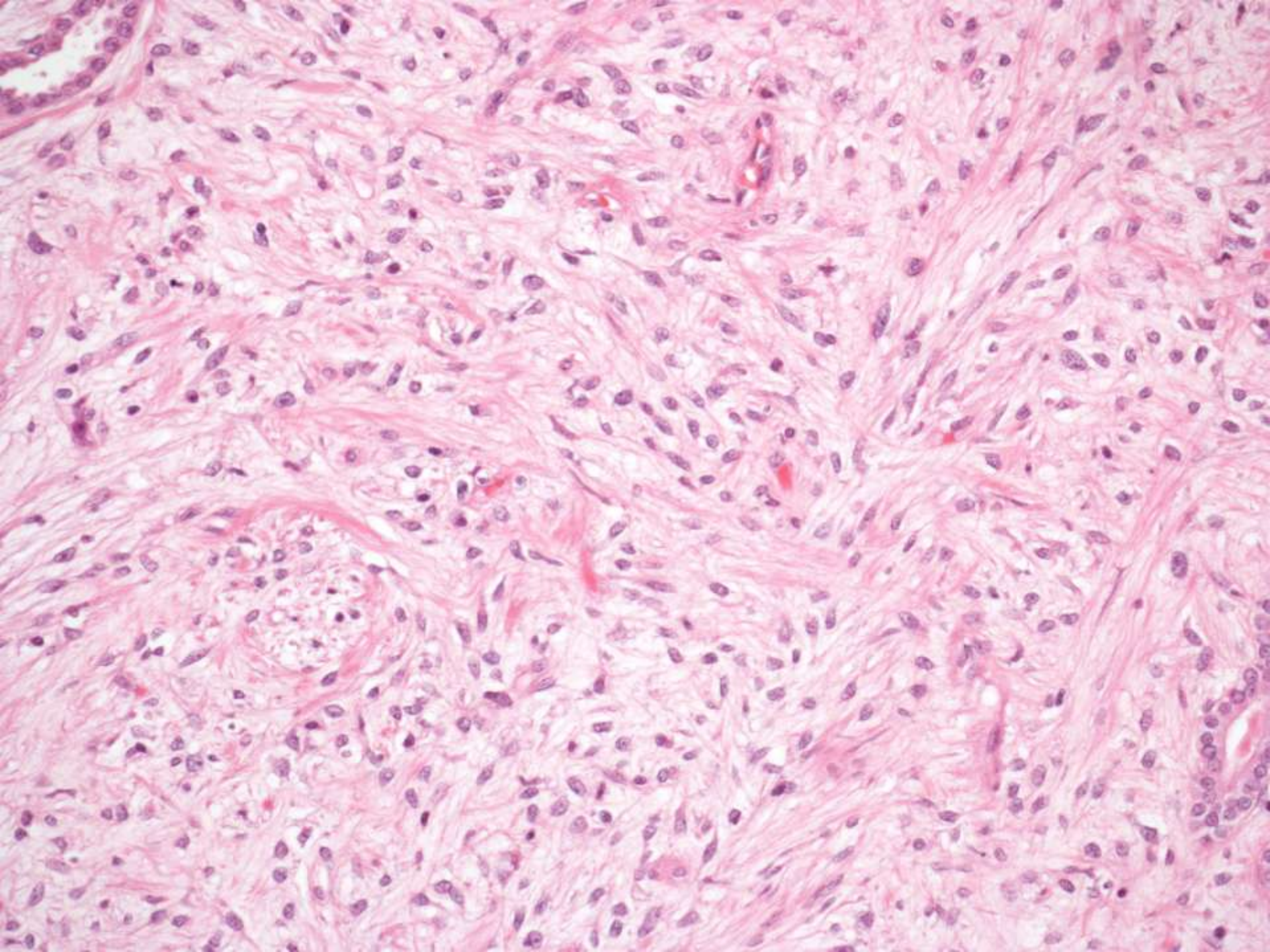
- 54 year old female
 - Left kidney RCC
 - Incidental separate white nodule in medulla











Case E

- Diagnosis:
 - Renomedullary interstitial cell tumour / medullary fibroma

Case E

- Responses:
 - Score 1
 - 112 - Renomedullary interstitial cell tumour / medullary fibroma
 - Score 2
 - 1 - Metanephric adenofibroma
 - 1 - Benign fibrous nodule
 - Score 3
 - 1 – ‘Show it to a specialist colleague’

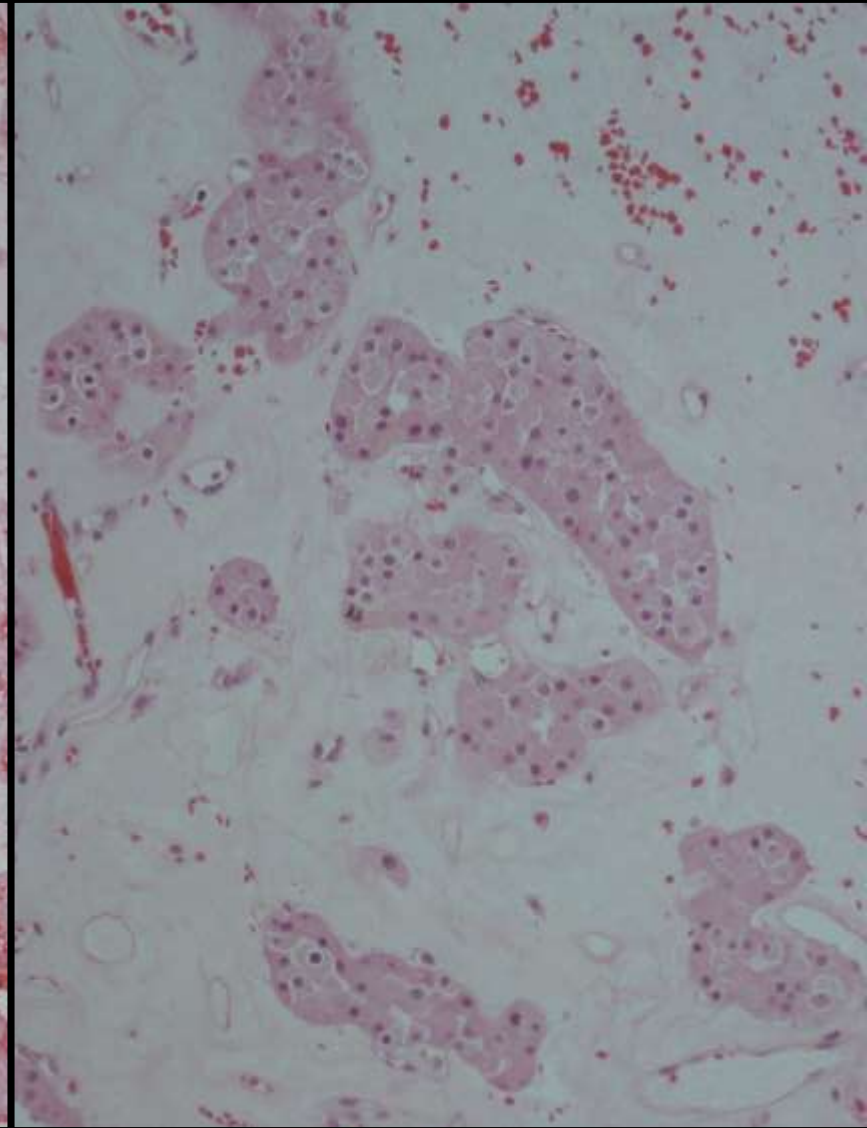
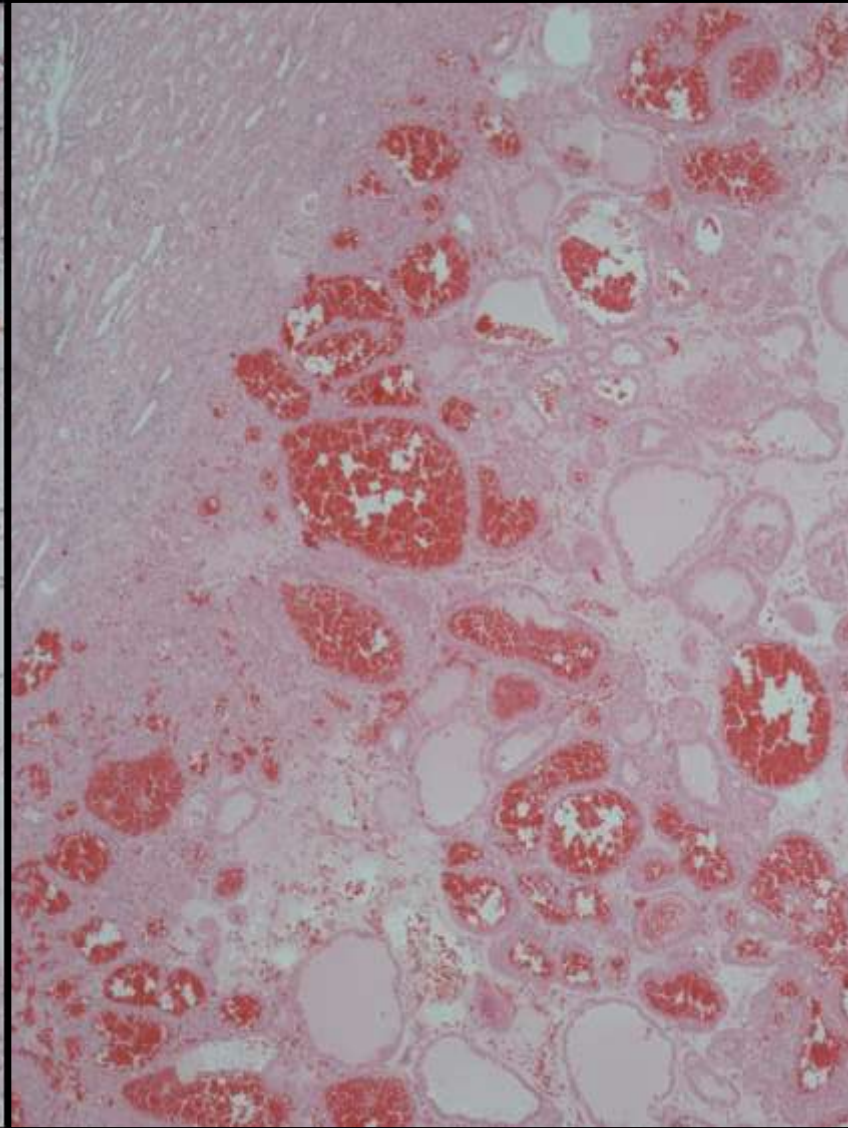
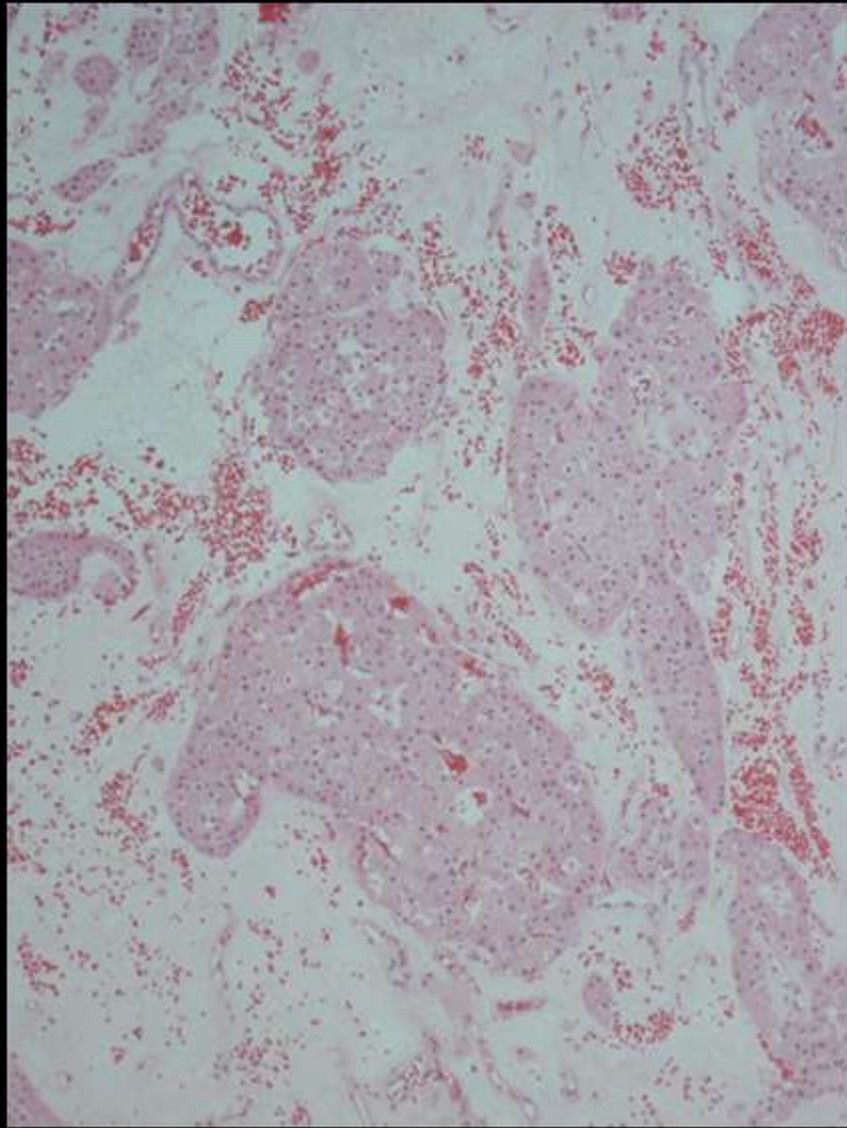
Scotland and Northern Ireland General EQA Scheme

Circulation 48
Cases F – J

Submitted by Dr K Struthers

Case F

- 55 year old female
- 3 cm lesion lower pole kidney
- Partial nephrectomy



Case F

- Diagnosis:
- Renal oncocytoma

Case F

- Responses:

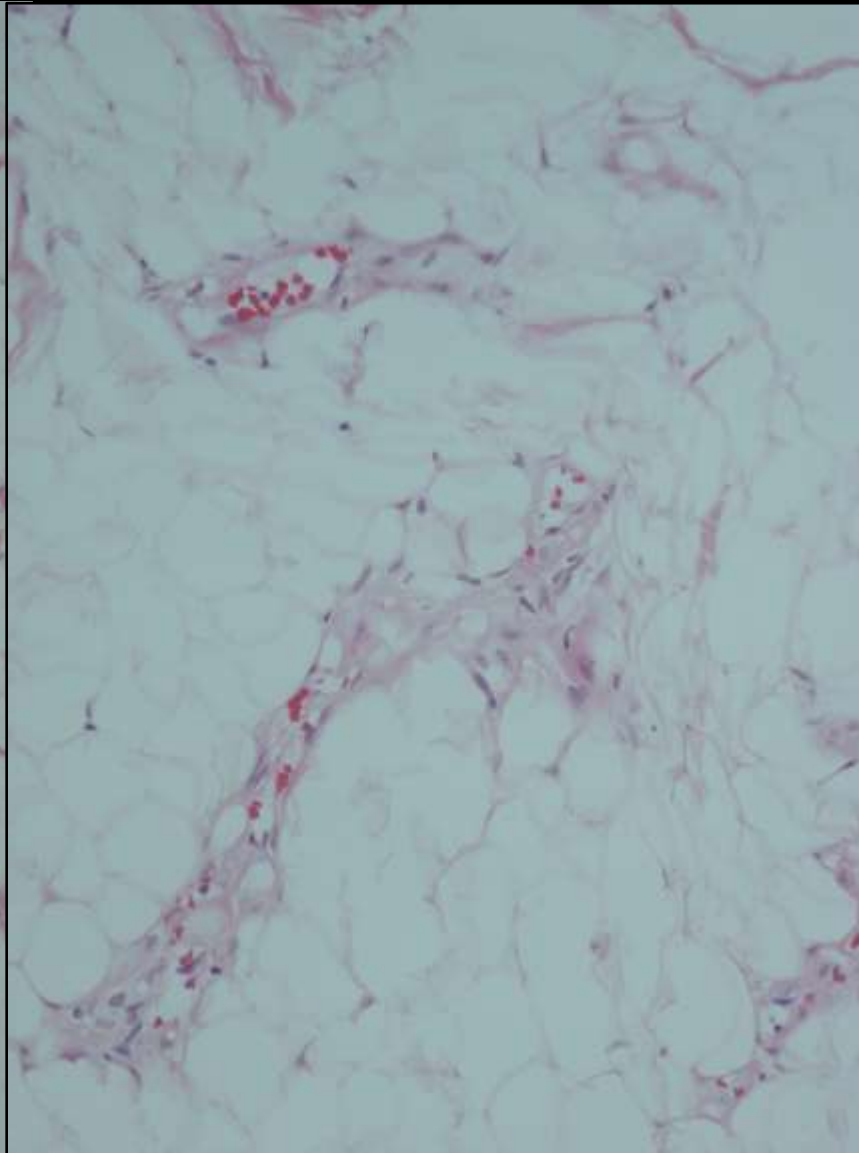
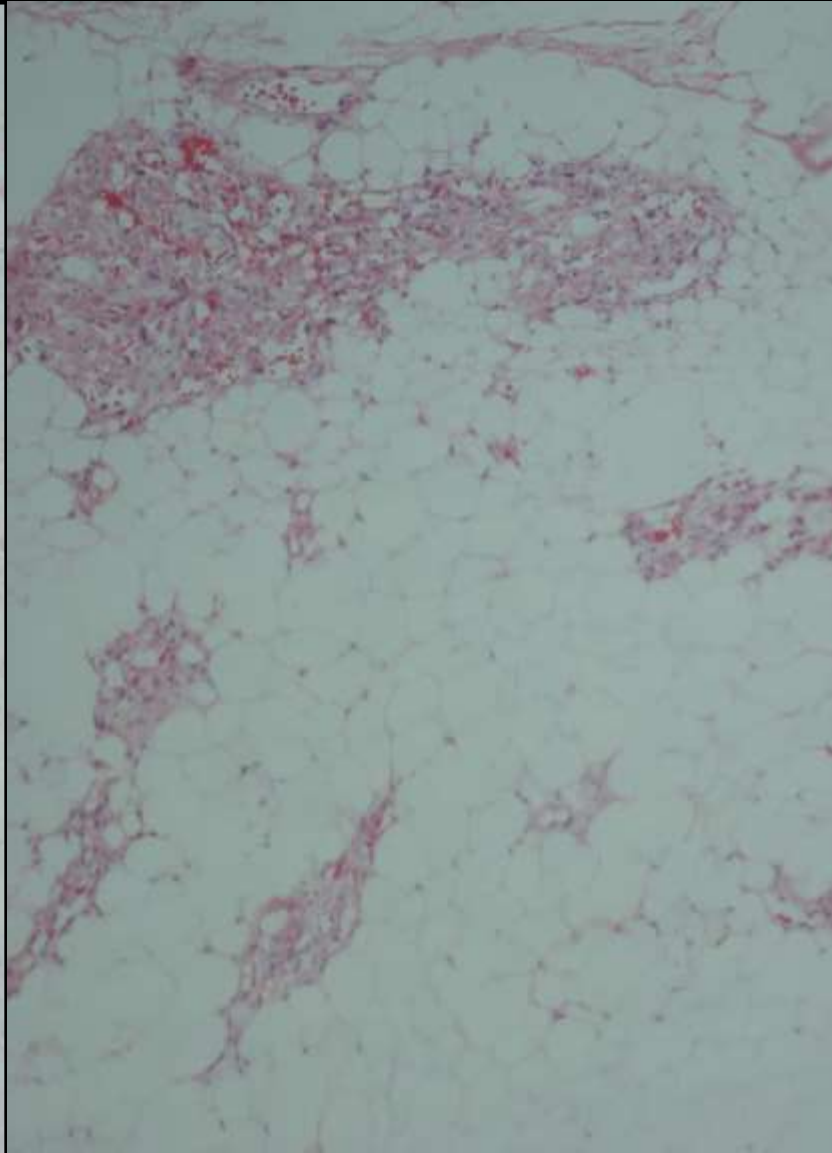
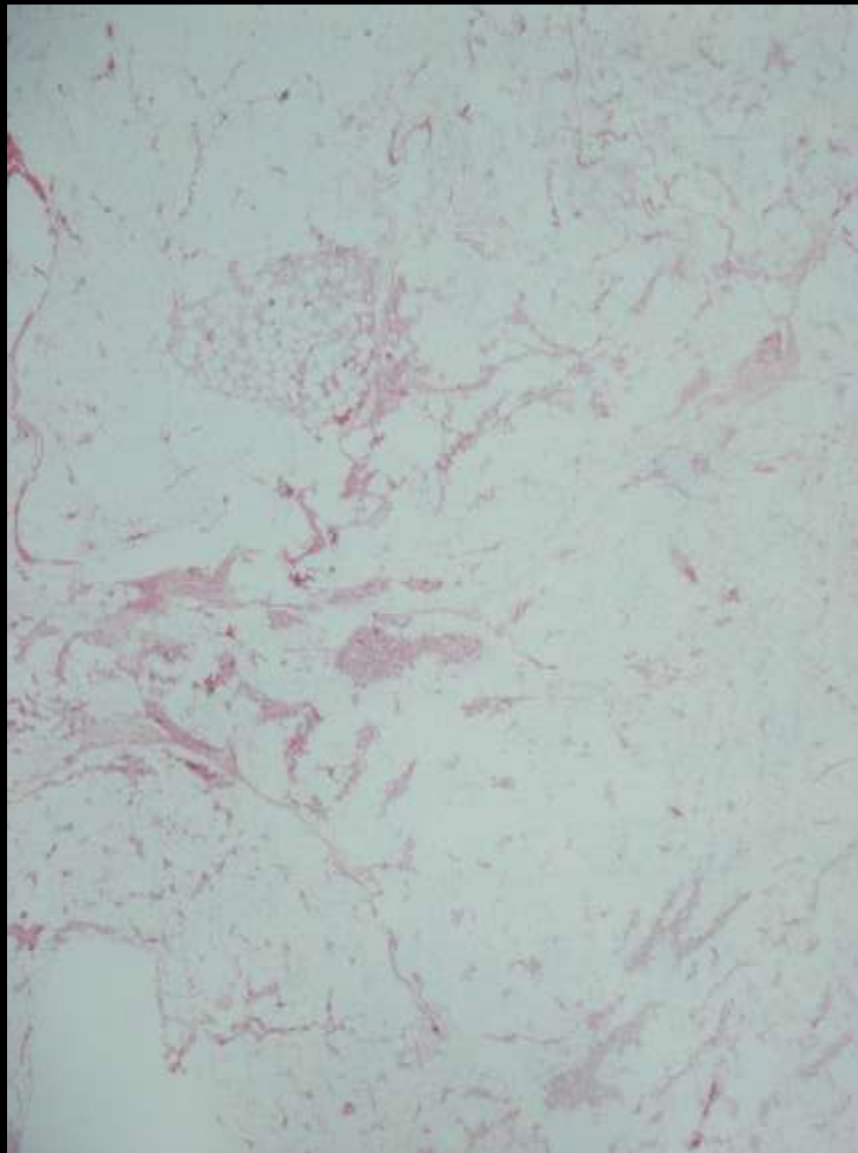
- **Score 1**

- 114 - Oncocytoma

- 1 - Oncocytoma / multicystic RCC, needs ICC

Case G

- 50 year old female
- Multiple lesions on arms
- Lesion left forearm increasing in size and causing discomfort



Case G

- Diagnosis:
- Angiolipoma

Case G

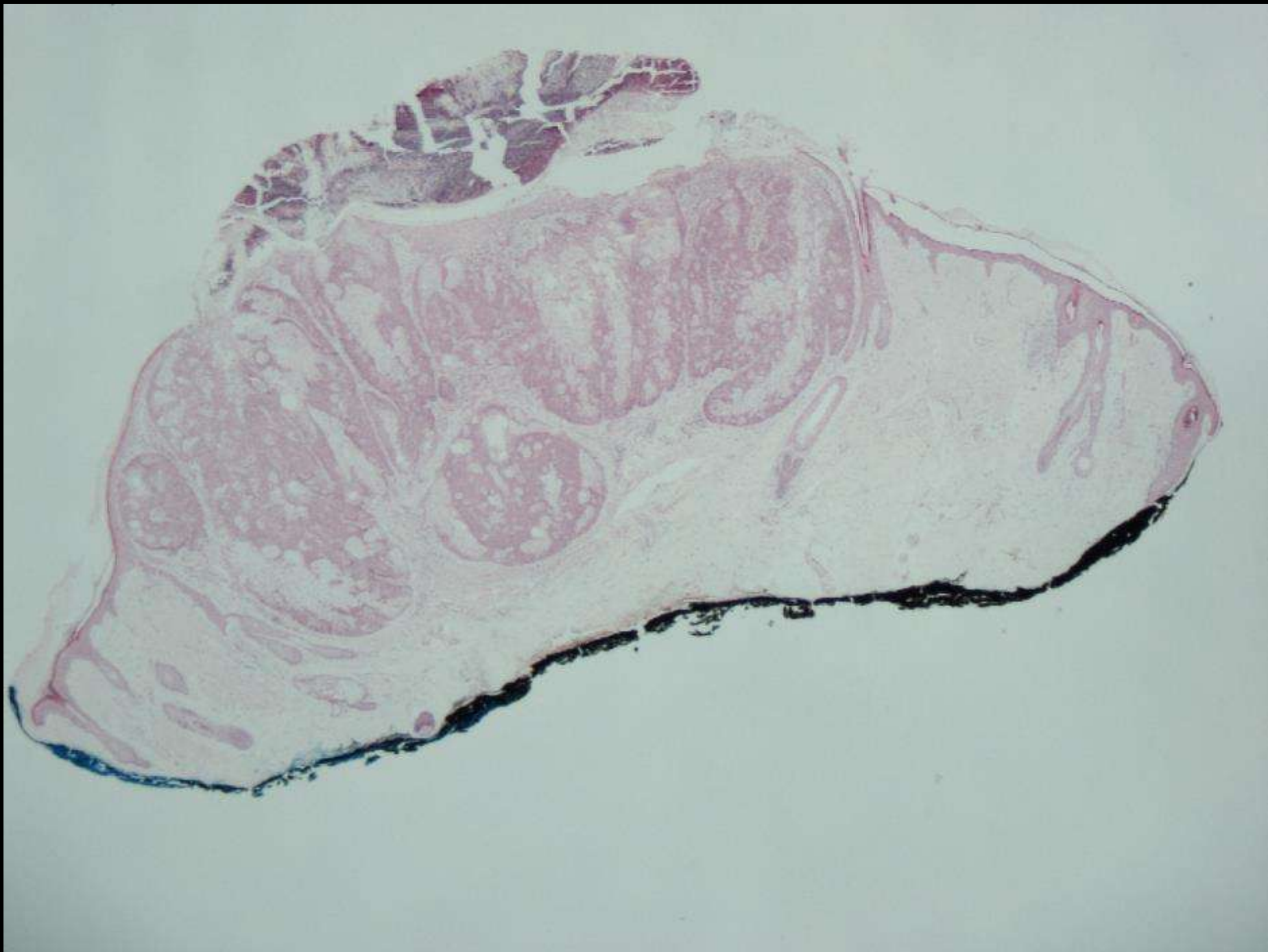- Responses:

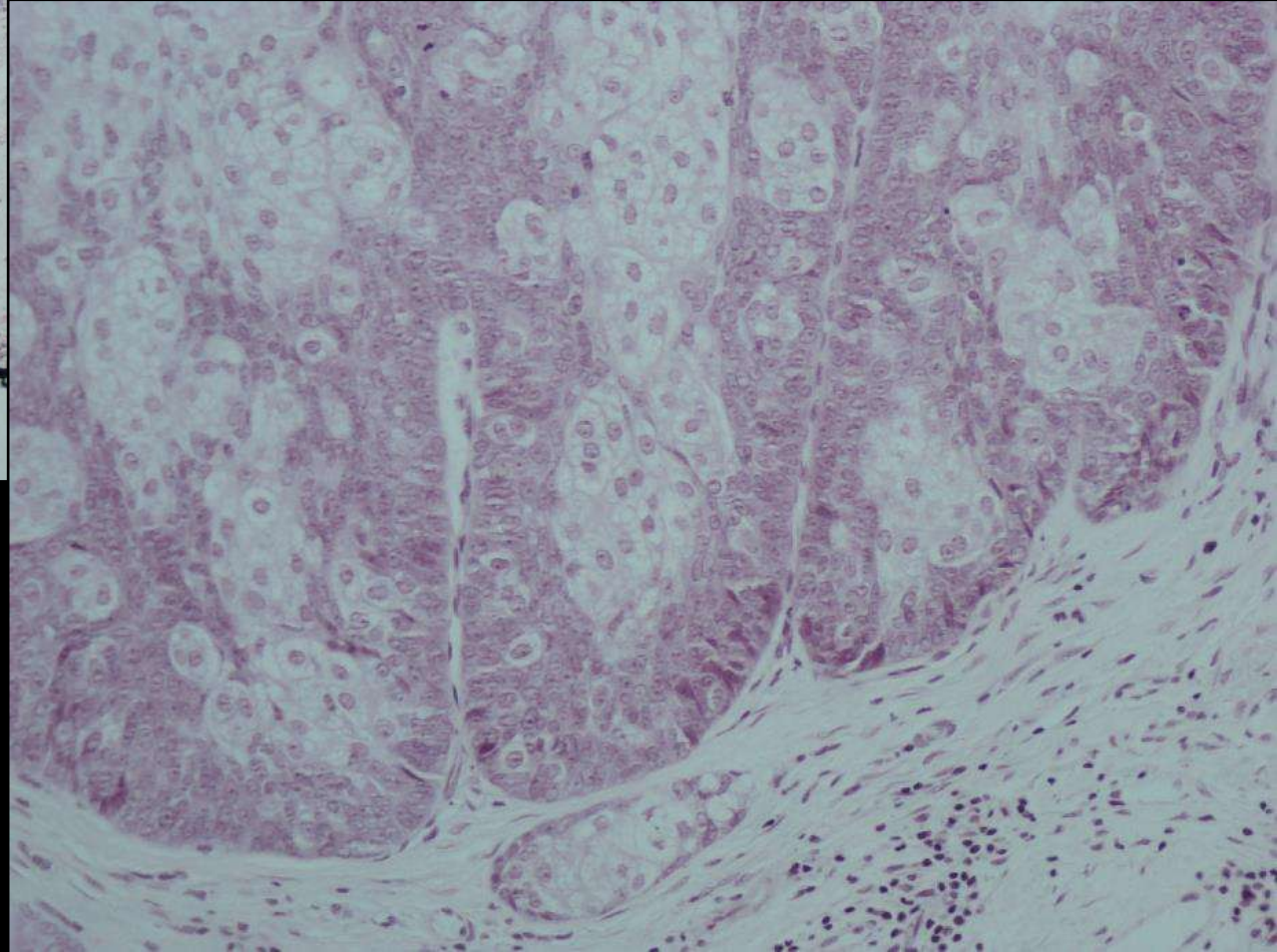
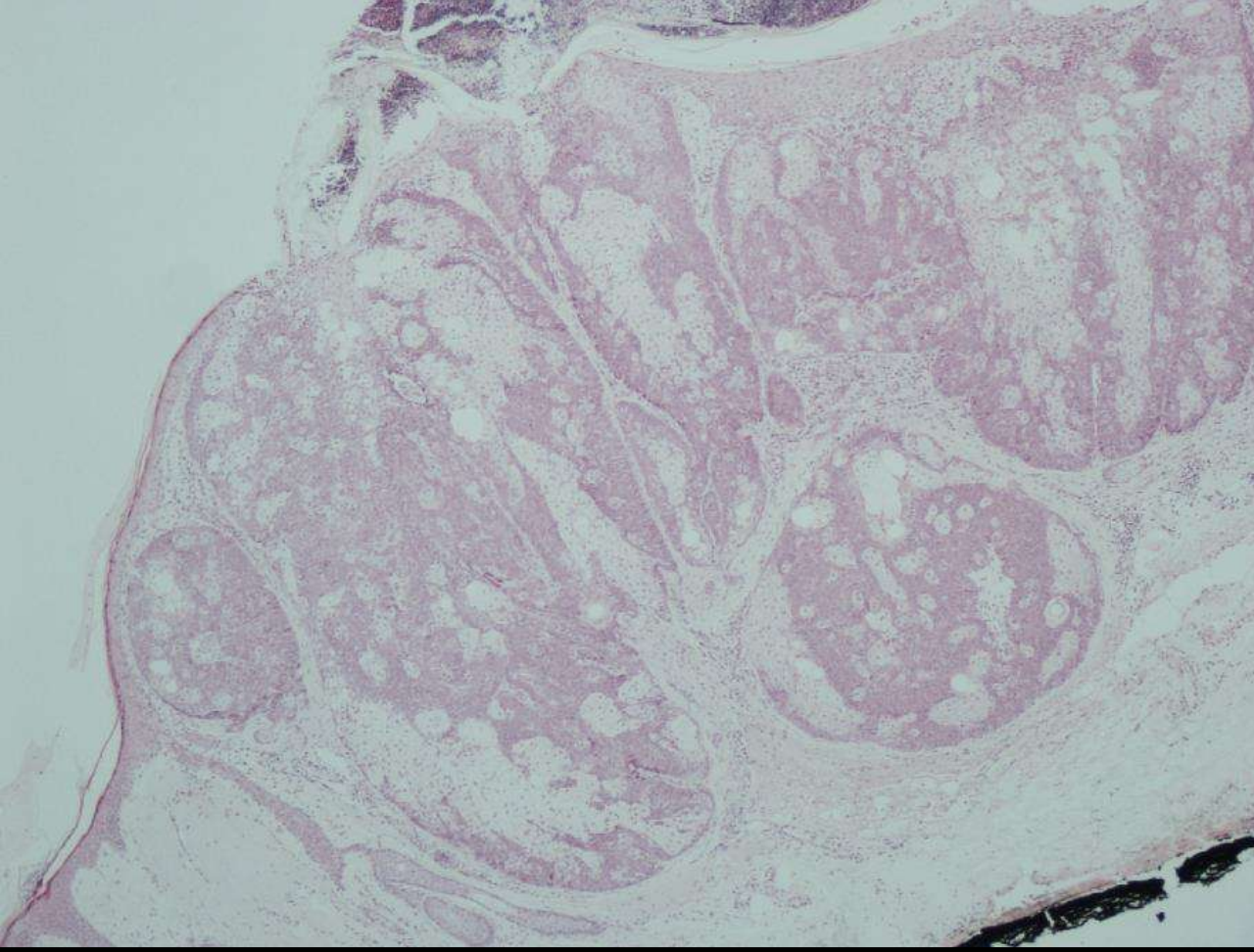
- **Score 1**

- 115 – Angiolipoma

Case H

- 84 year old female
- Skin lesion on forehead





Case H

- Diagnosis:
- Sebaceoma

Case H

- Responses:

- **Score 1**

- 45 - Sebaceoma
- 68 - Sebaceous adenoma

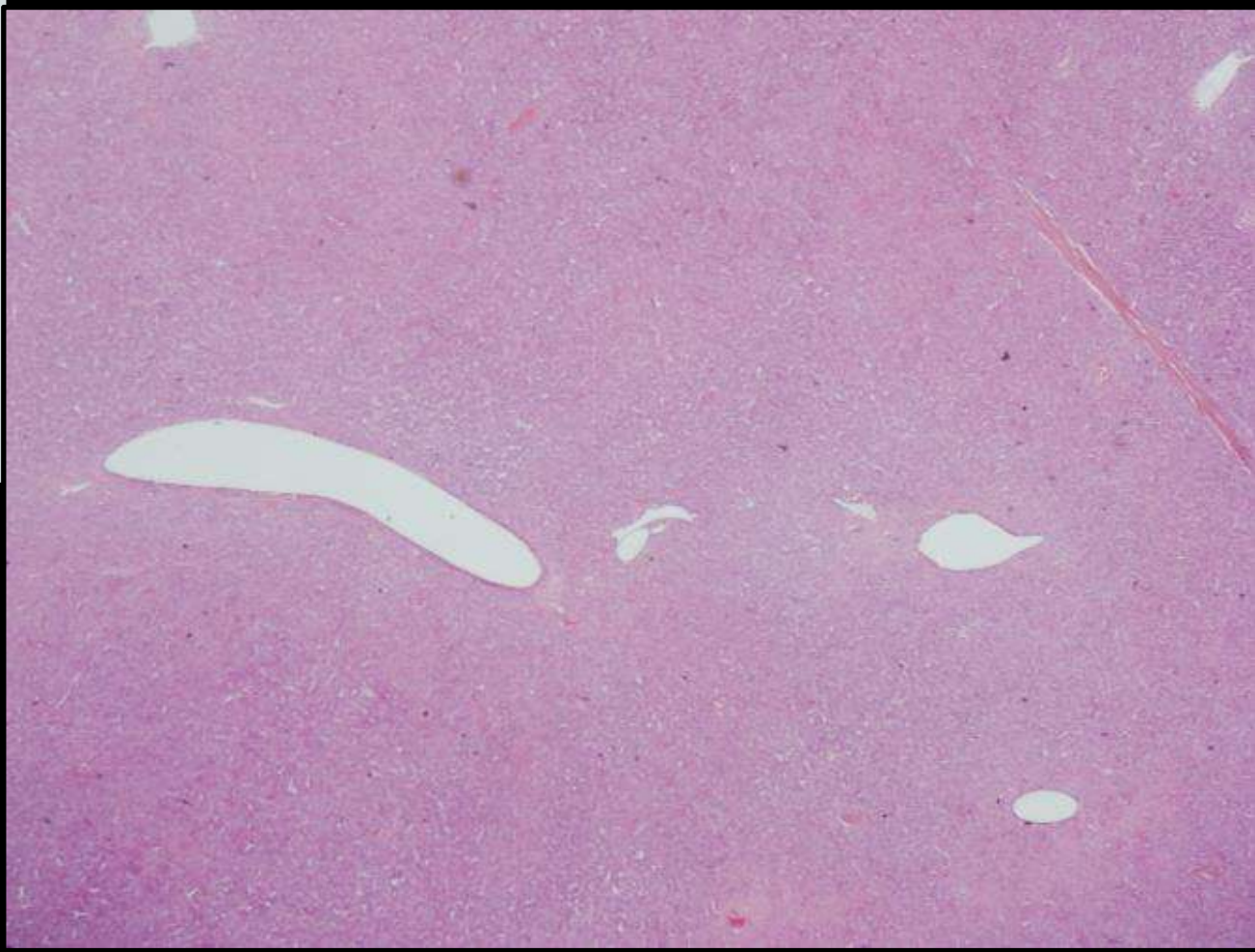
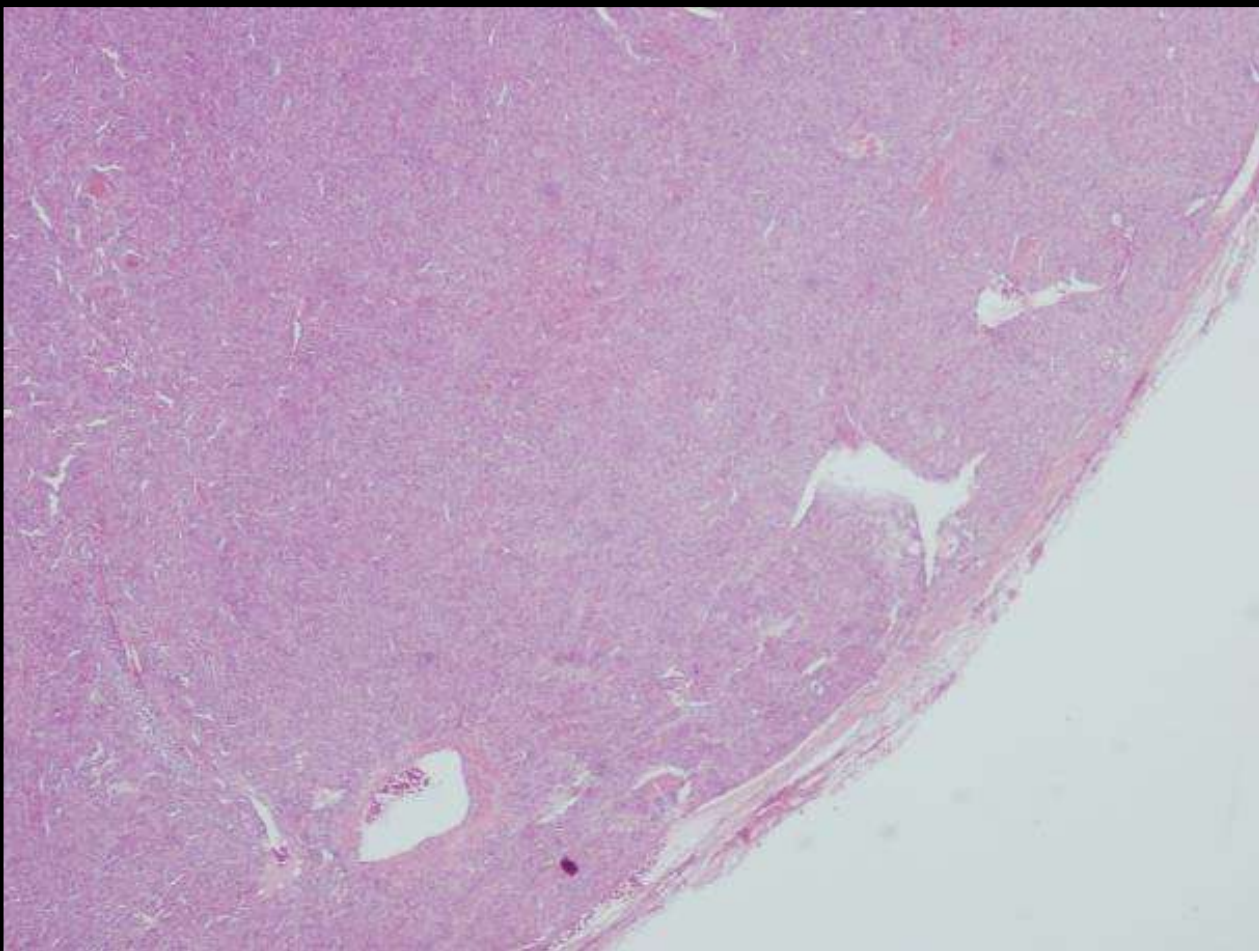
(some mentioned association with Muir-Torre syndrome)

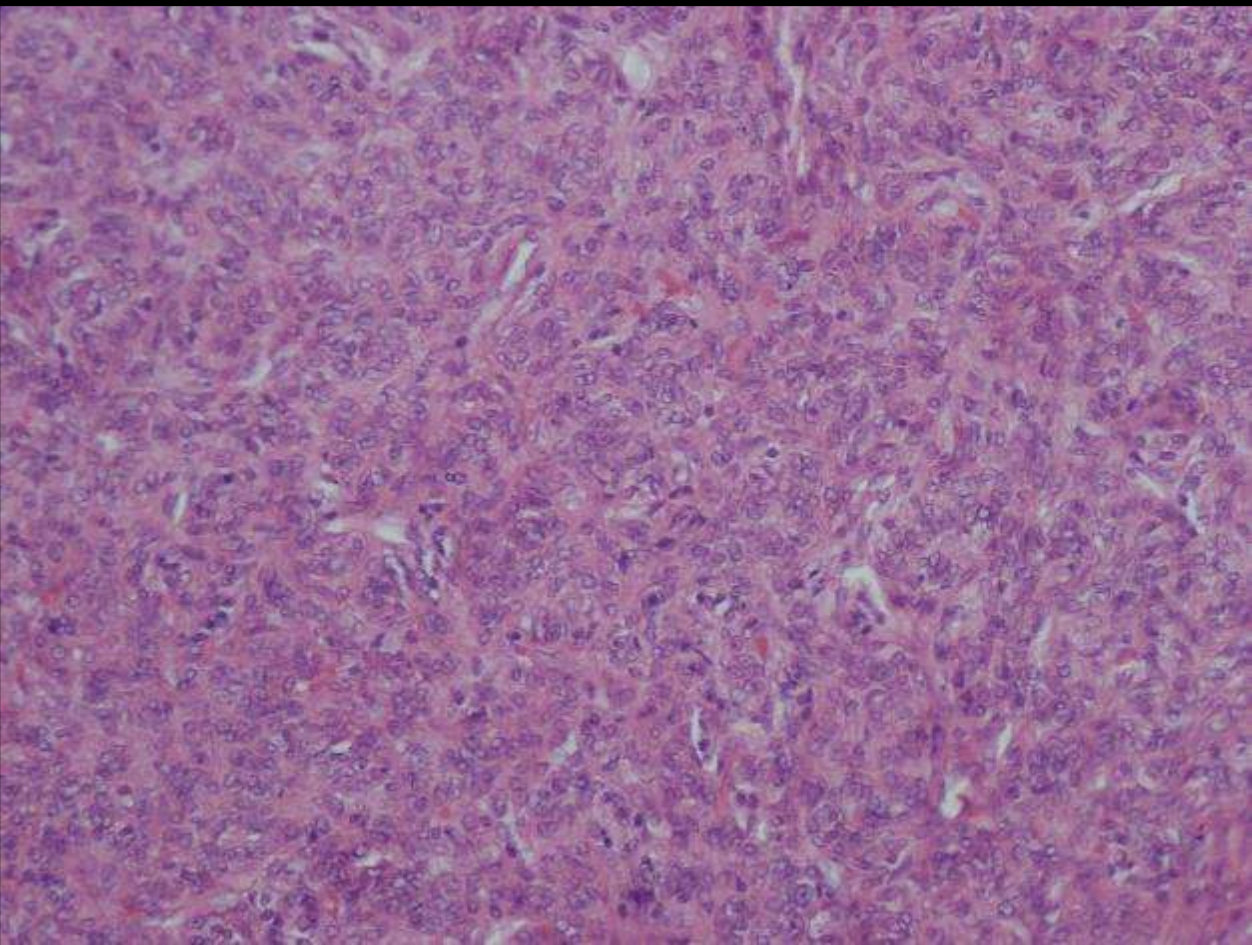
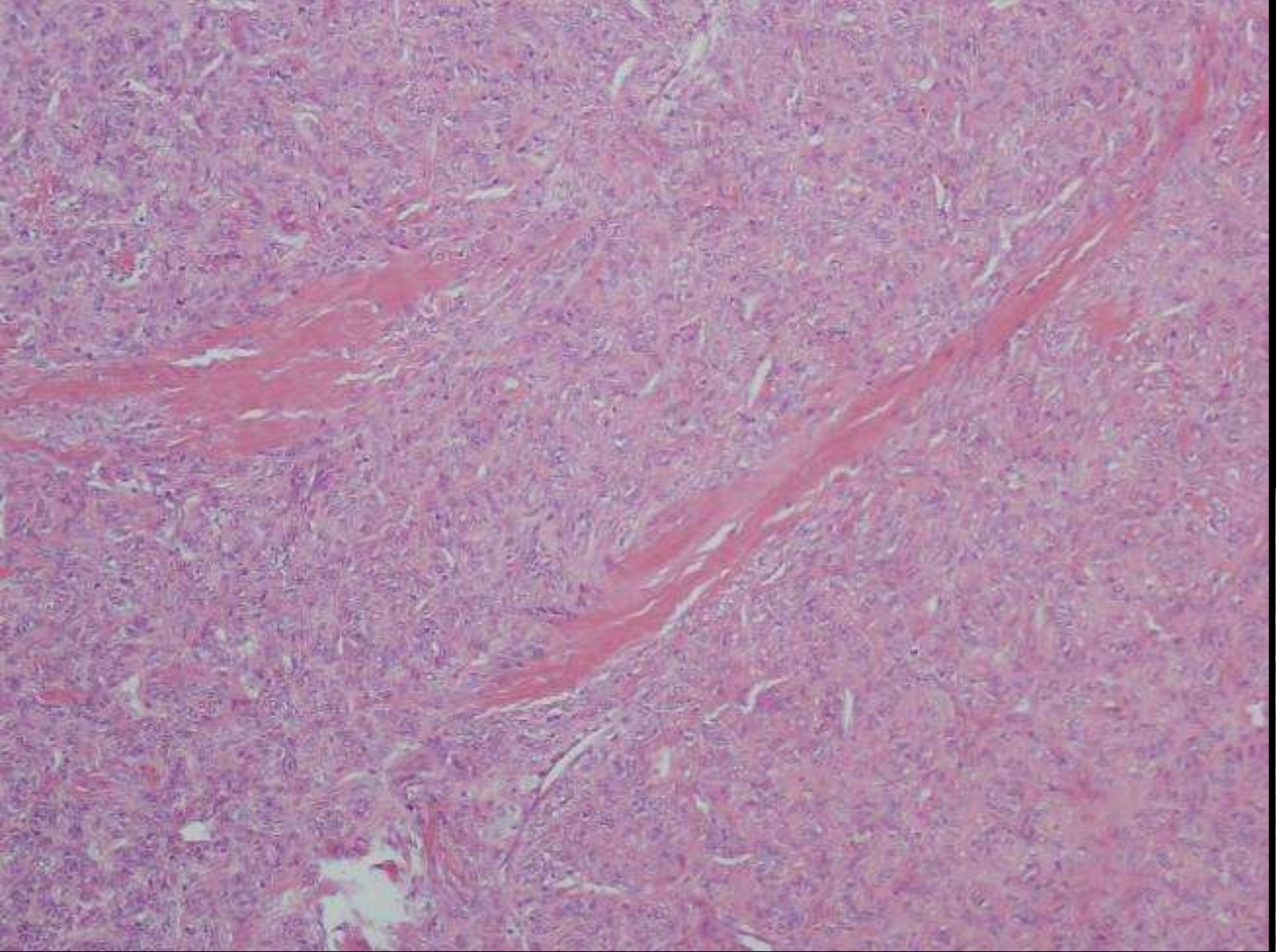
- **Score 3**

- 2 – Sebaceous carcinoma

Case I

- 55 year old male
- Lump left groin
- Immunohistochemistry – positive for CD34, CD99 and Vimentin;
Negative for SMA, Desmin and S100





Case I

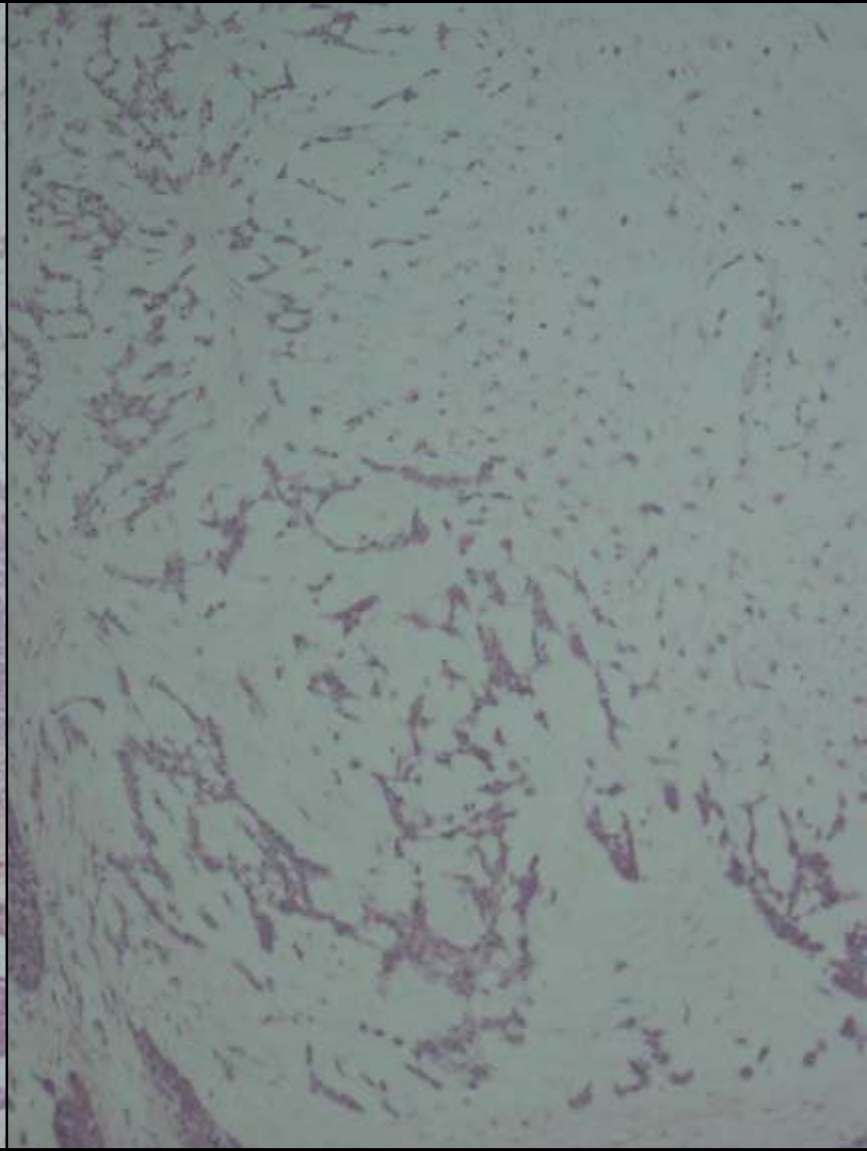
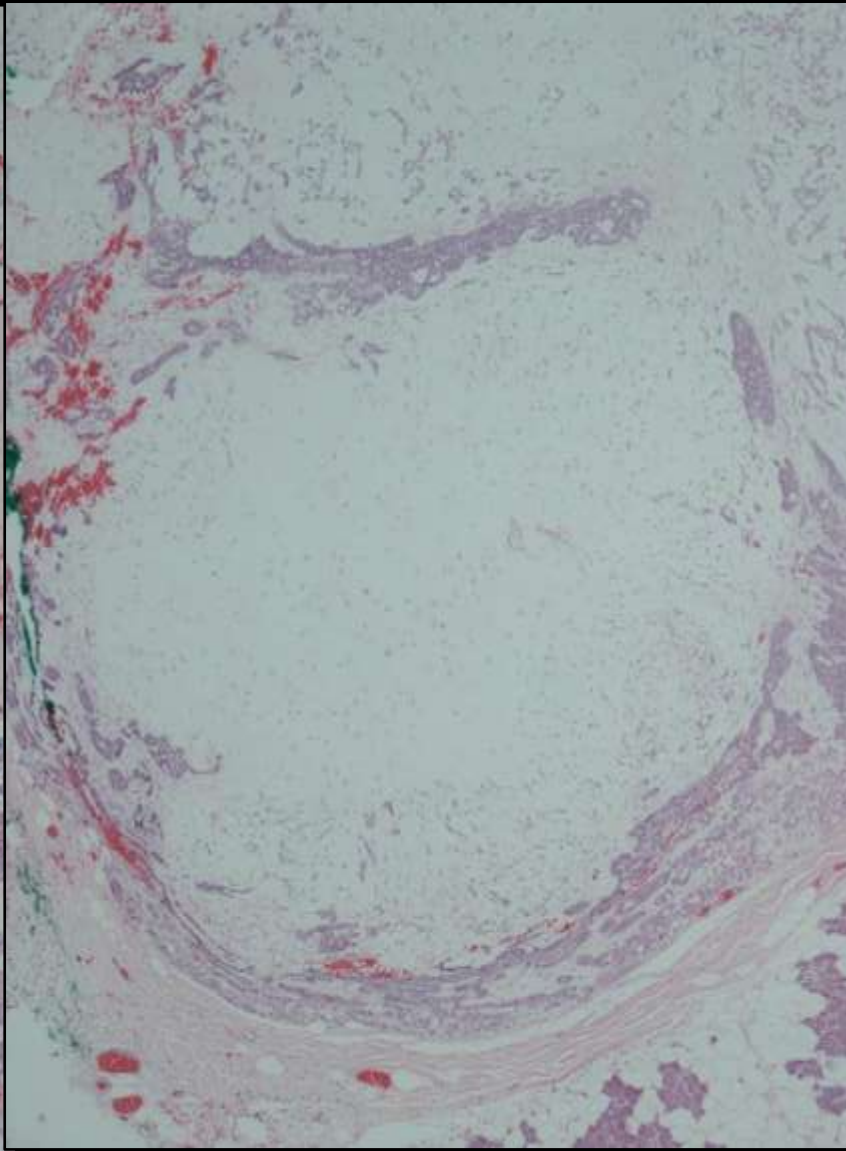
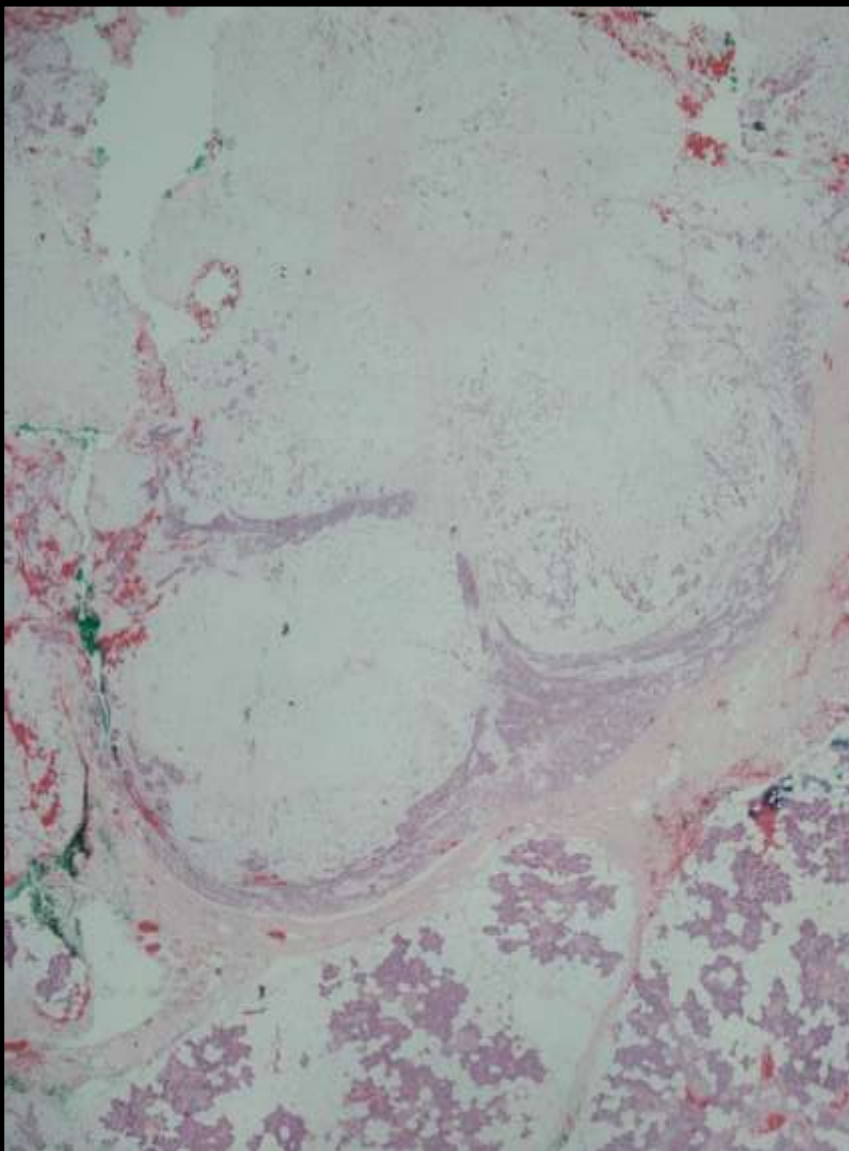
- Diagnosis:
- Solitary fibrous tumour

Case I

- Responses:
- **Score 1**
- 113 – Solitary fibrous tumour
(some stated would confirm with STAT 6 IHC)
- 1- Haemangiopericytoma
- **Score 2**
- 1 – Myofibroblastoma

Case J

- 50 year old female
- Right parotid gland lesion



Case J

- Diagnosis:
- Pleomorphic salivary adenoma

Case J

- Responses:
- **Score 1**
- 114 - Pleomorphic salivary adenoma / pleomorphic adenoma / PSA
- 1 – PSA on background of Mikulicz's disease

