

Scotland and Northern Ireland EQA scheme

Circulation 43

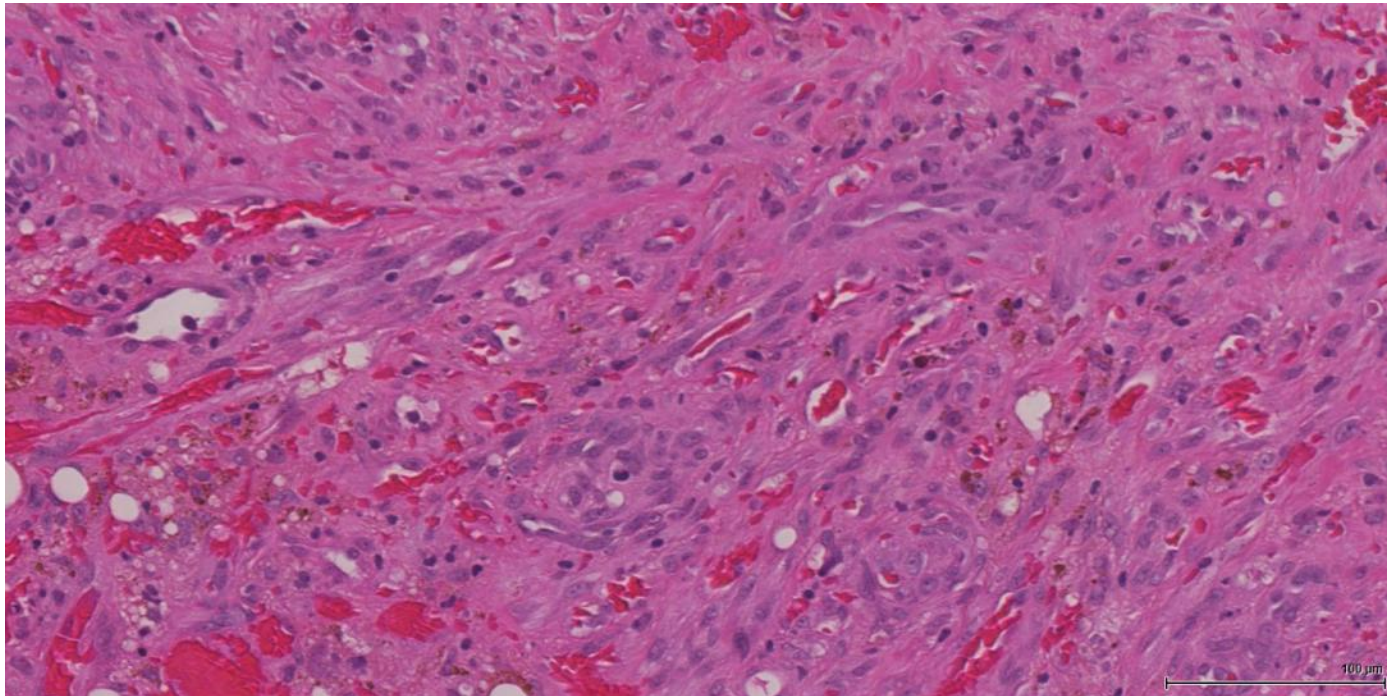
Cases 1-5

Case 1

- 57 year old male
- Myeloma and immunosuppressed.
- Purple lesions
- CD31, CD34 and HHV-8 positivity

Kaposi's Sarcoma

- Kaposi's Sarcoma (1)
- Angiosarcoma (Kaposi's sarcoma) (1)

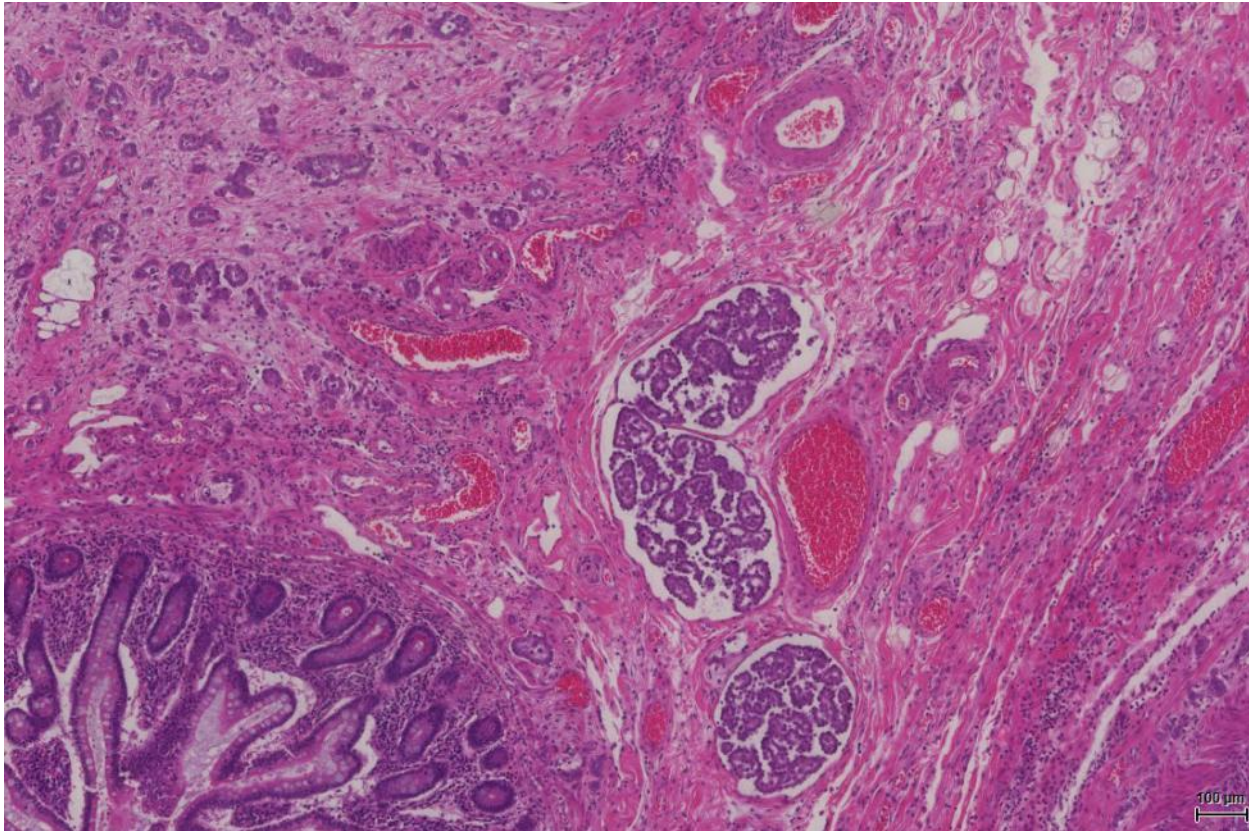


Case 2

- 74 female
- Bowel resection, bowel strictures
- History of colorectal carcinoma and mesothelioma
- ICC – CK5, CK7, calretinin positive; Berp4, CK20, CDX-2, ER, PR TTF-1 negative

Mesothelioma

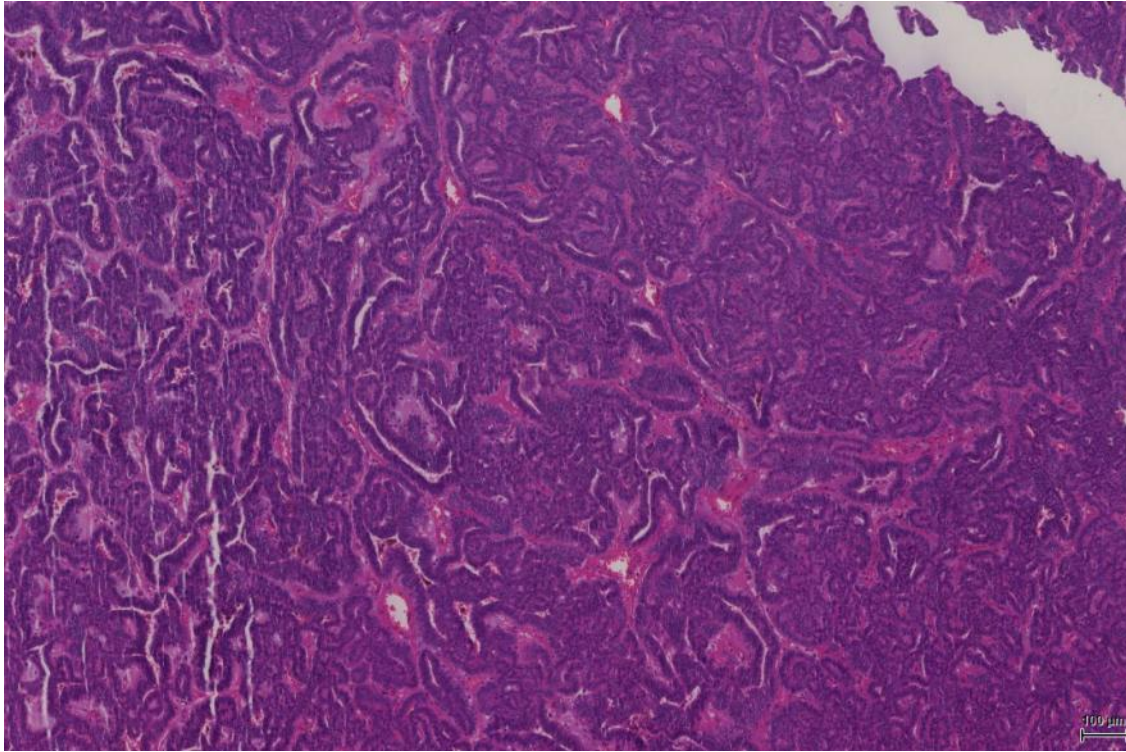
- Mesothelioma (1)



Case 3

- 60 female
- Lip swelling 12 months
- ? Salivary gland tumour
- Biopsy right upper lip

Canalicular Adenoma



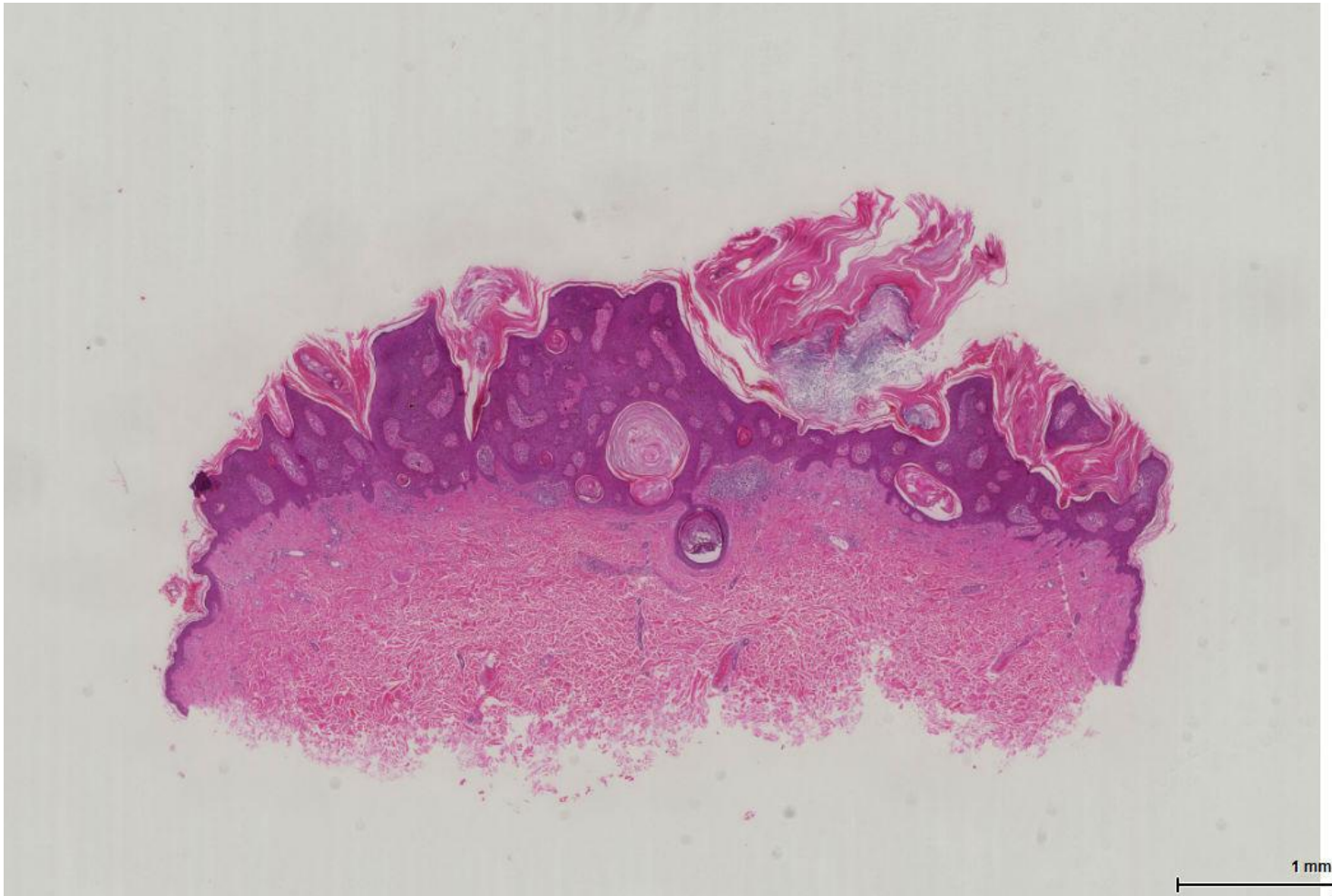
- Canalicular adenoma (1)
- Basal cell adenoma, monomorphic adenoma (1)
- Trabecular adenoma, basaloid adenoma (2)
- Intraduct papilloma (2)

Case 4

- 65 male
- Pigmented lesion n abdomen
- Increasing in size
- Satellite lesions

Seborrhoeic Keratosis

- Seborrhoeic keratosis (1)
- Basal Cell Papilloma (1)

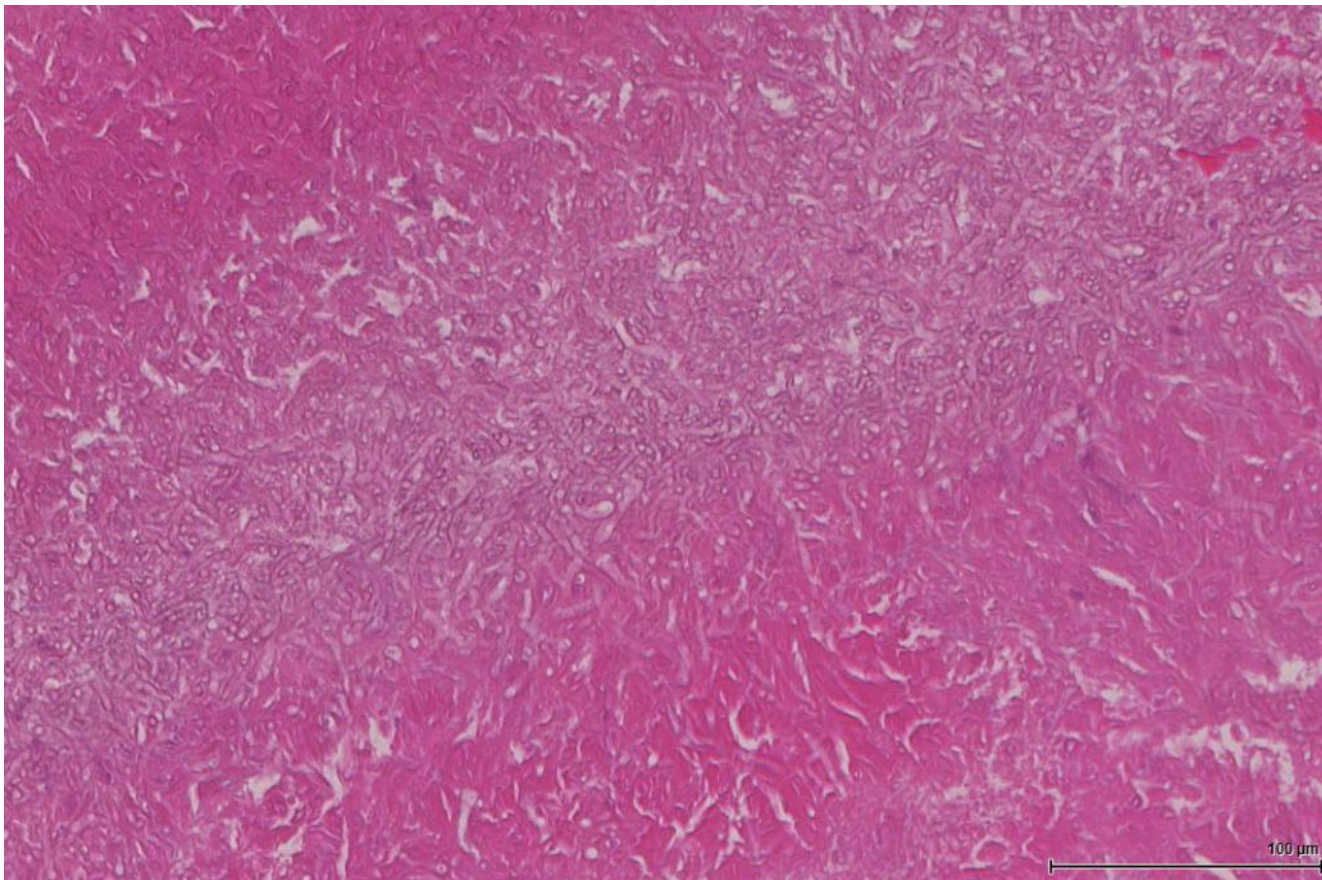


Case 5

- 41 yr old female
- Possible fungal sinusitis

Mycetoma/fungal ball

- Mycetoma/fungus (1)



EQA circulation 43

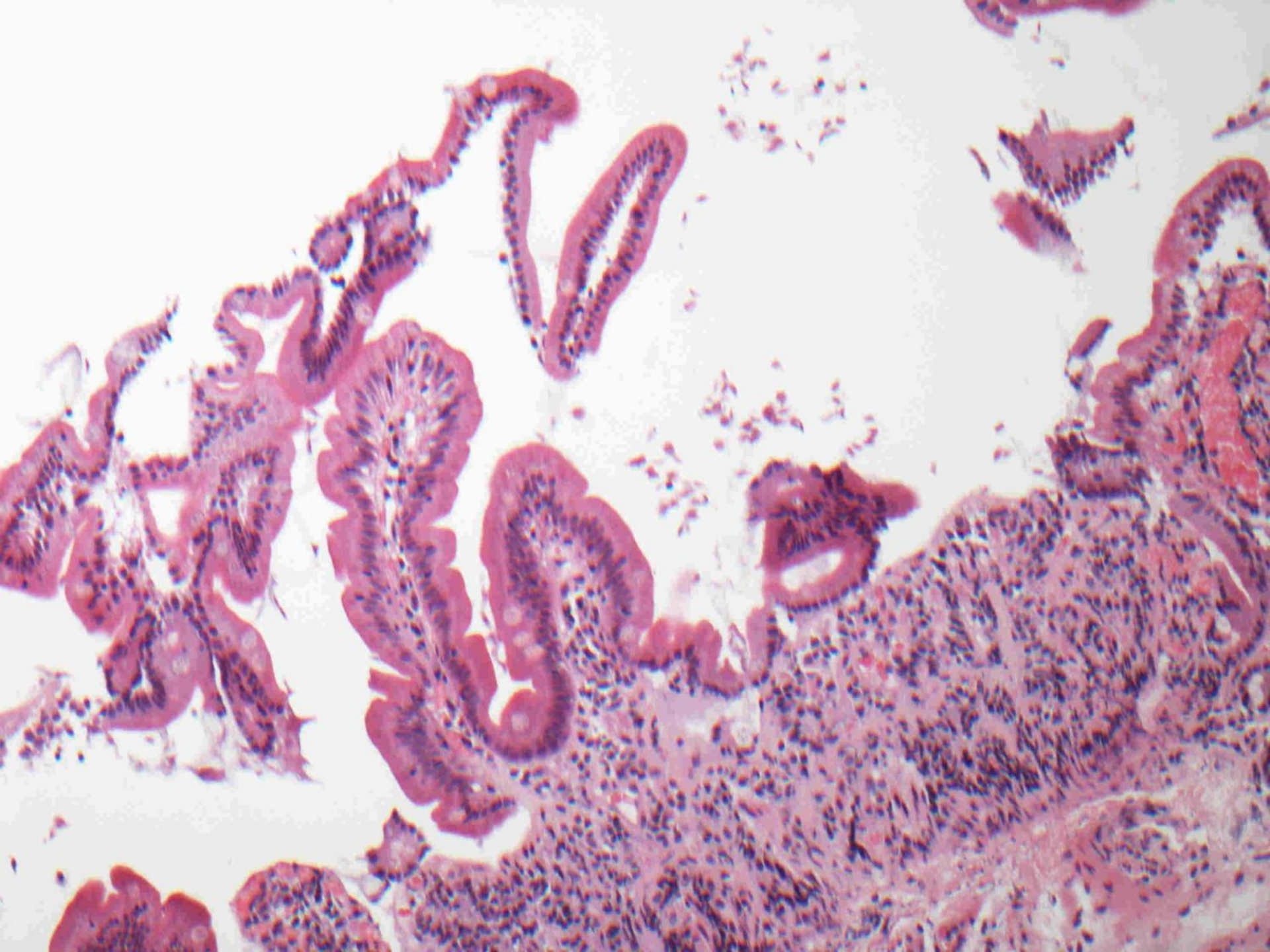
Cases F to J

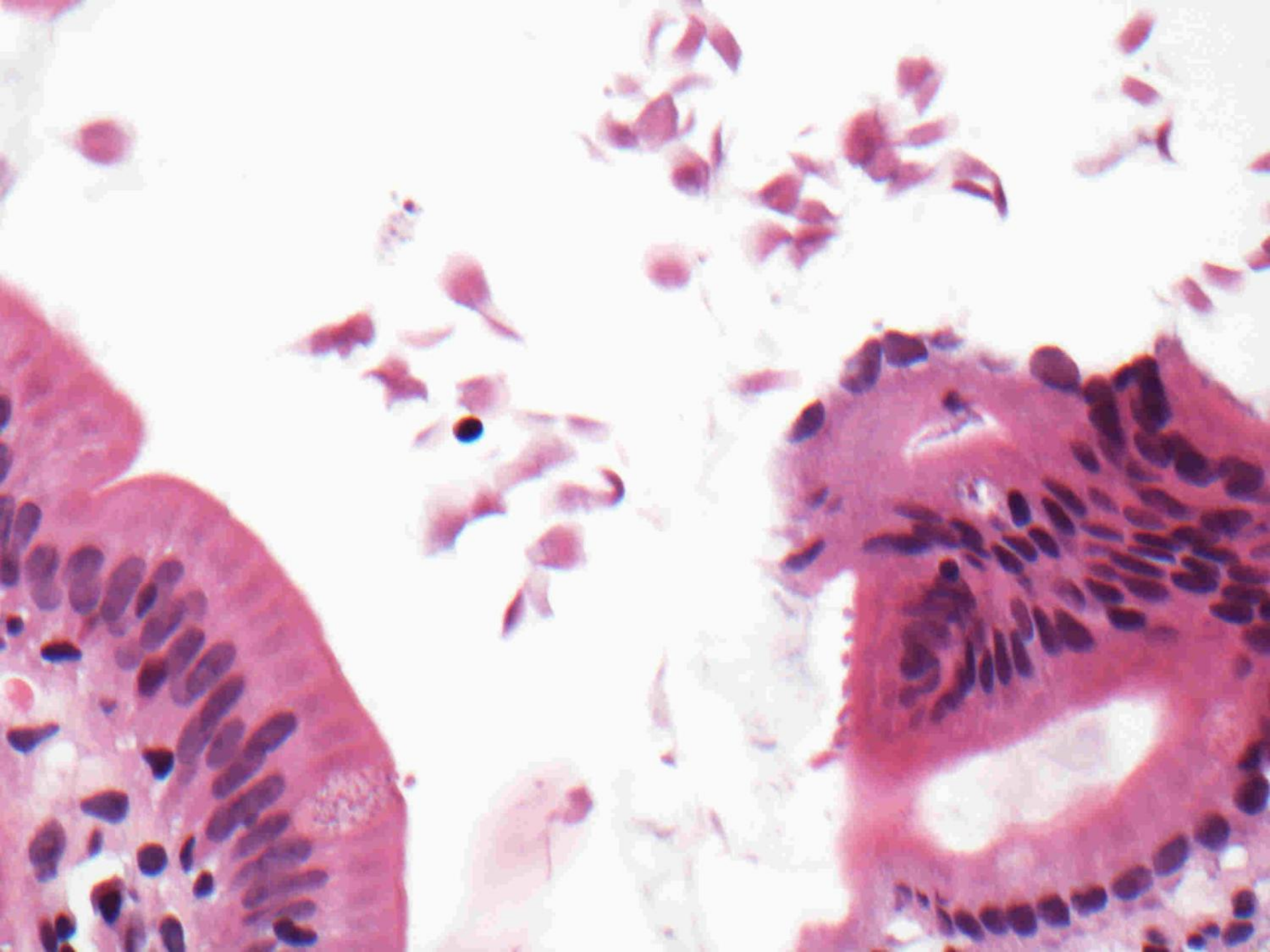
Marie Mathers

Western General Hospital, Edinburgh

Case F

- Female 20
- Abdominal pain, weight loss and diarrhoea
- Duodenal biopsies





Case F - Giardiasis

- 124 responses
- Score 1 – 122
- Score 2 - 2

Case F – score 1

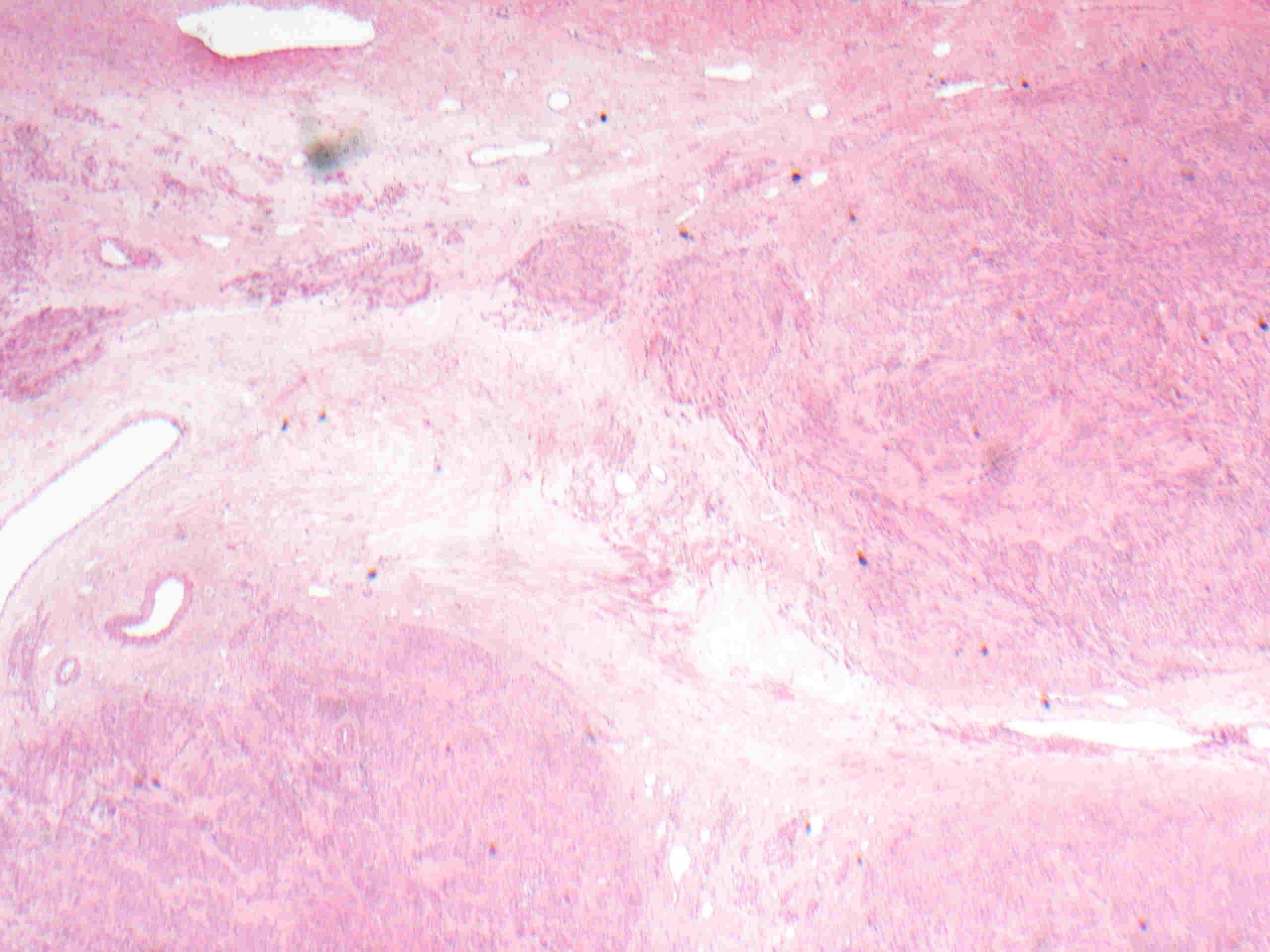
- Giardiasis

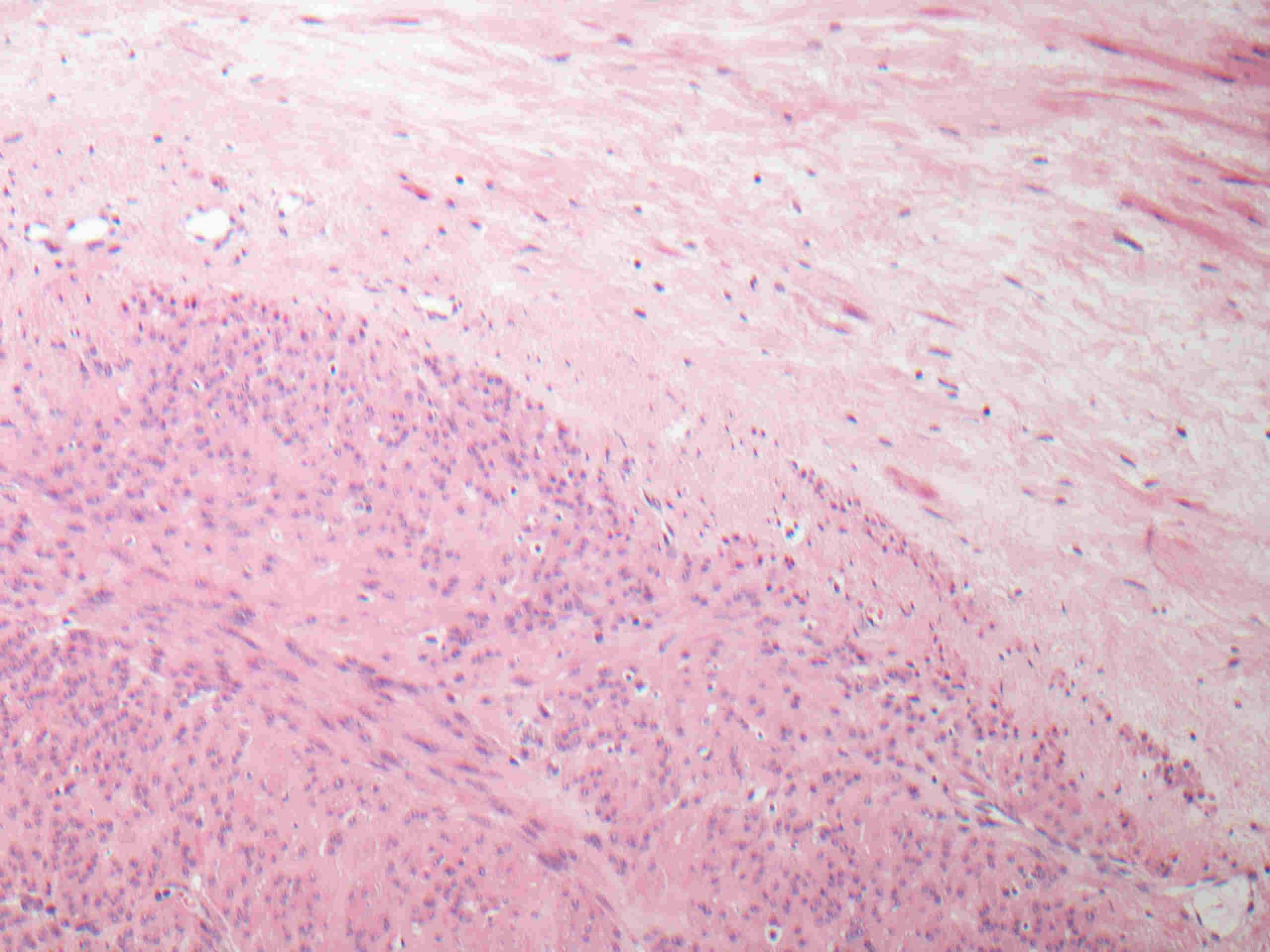
Case F – score 2 for discussion

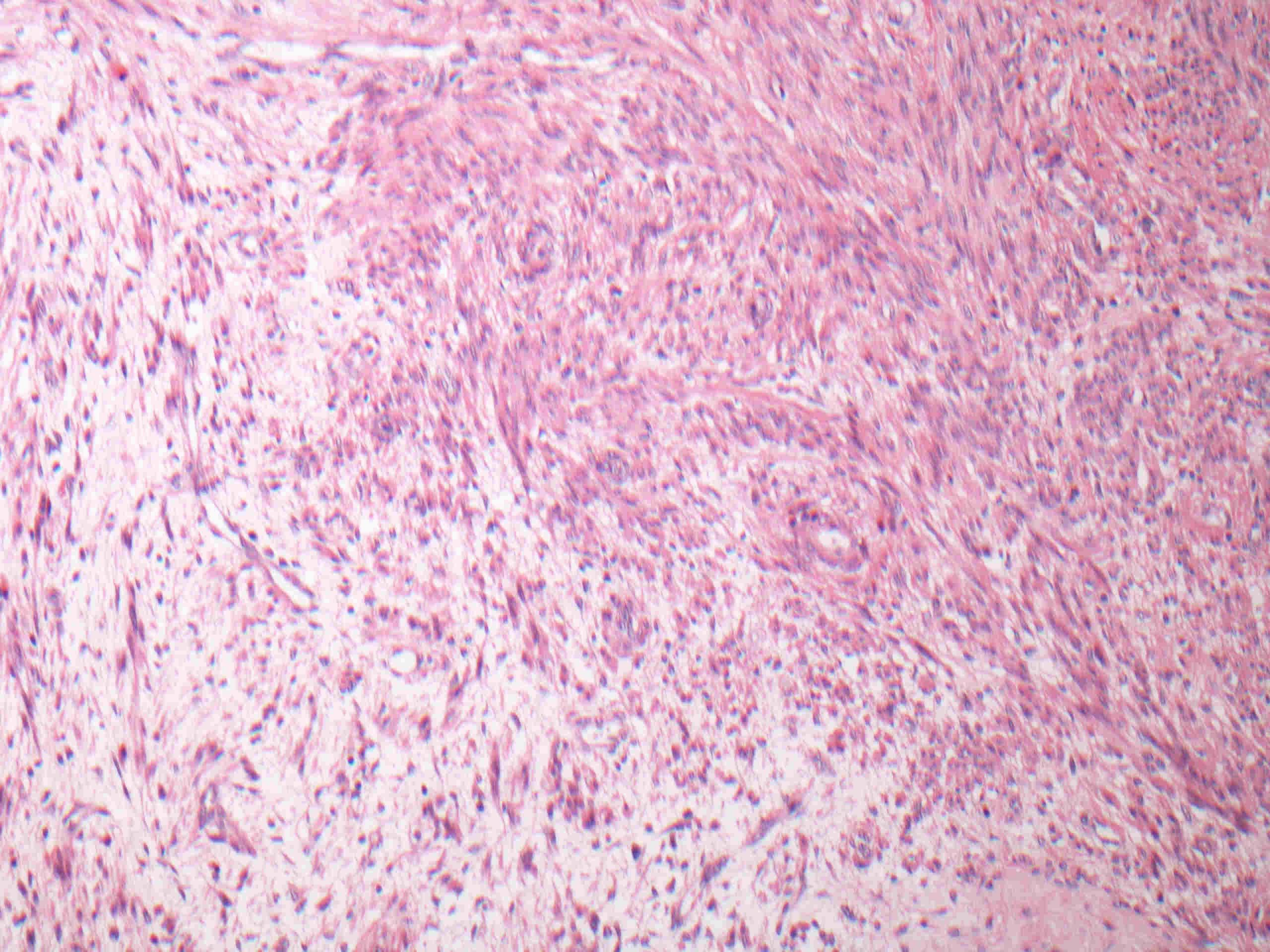
- Giardiasis & microsporidiosis

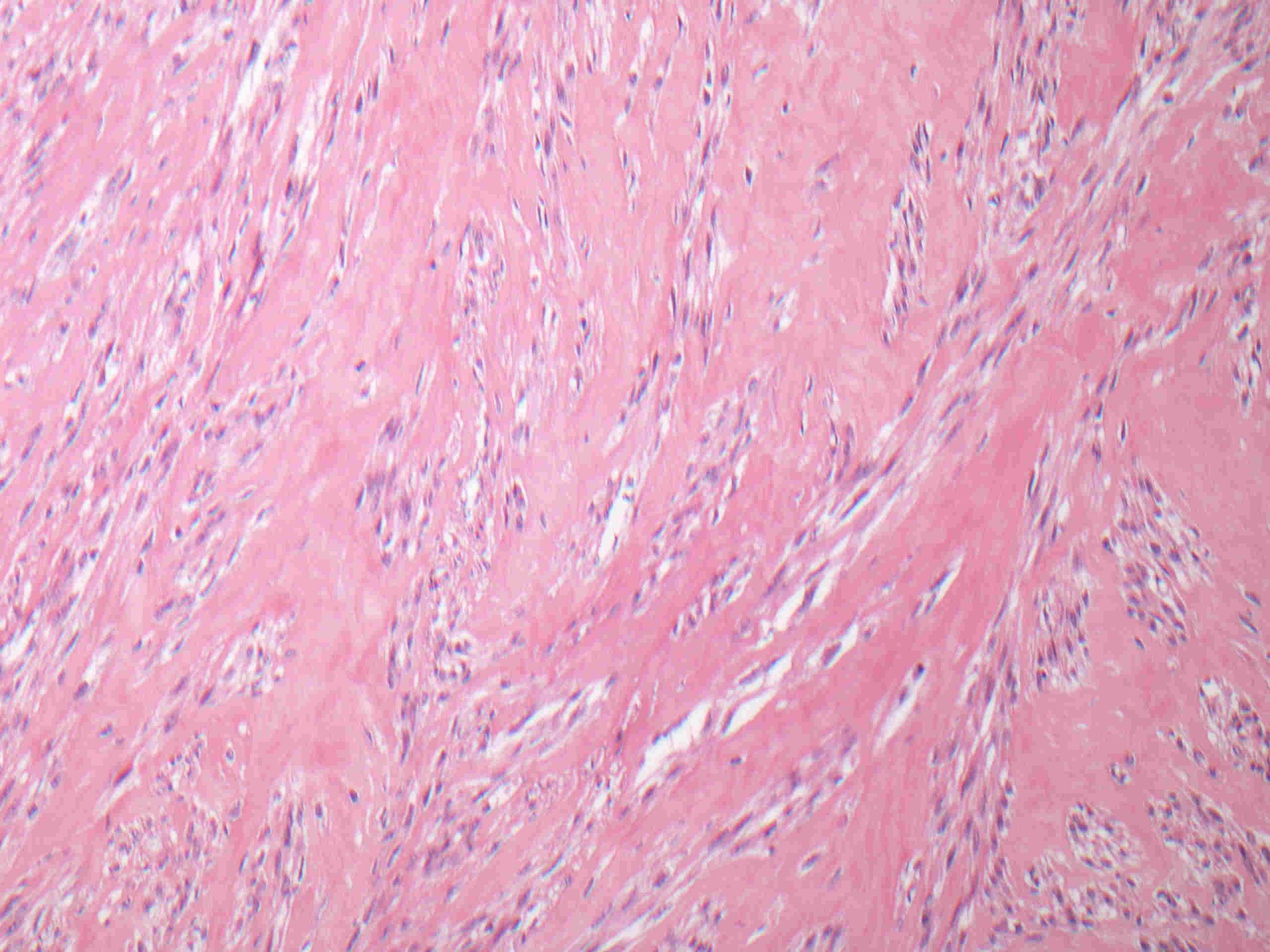
Case G

- Female 39
- Multiple uterine fibroids
- Myomectomy









Case G - Leiomyoma

- 124 responses
- Score 1 – 120
- Score 2 - 4

Case G – score 1

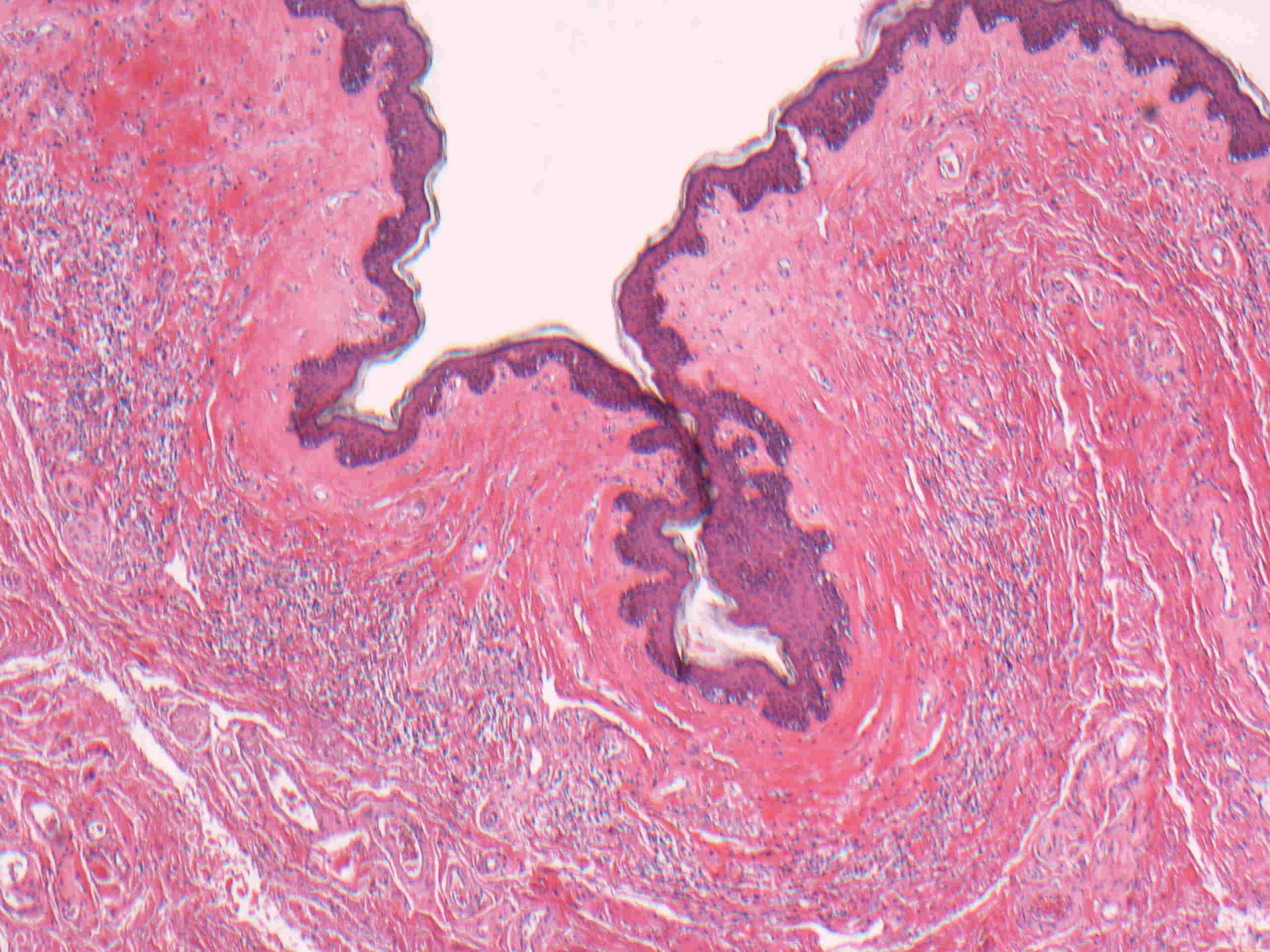
- Leiomyoma
- Fibroleiomyoma

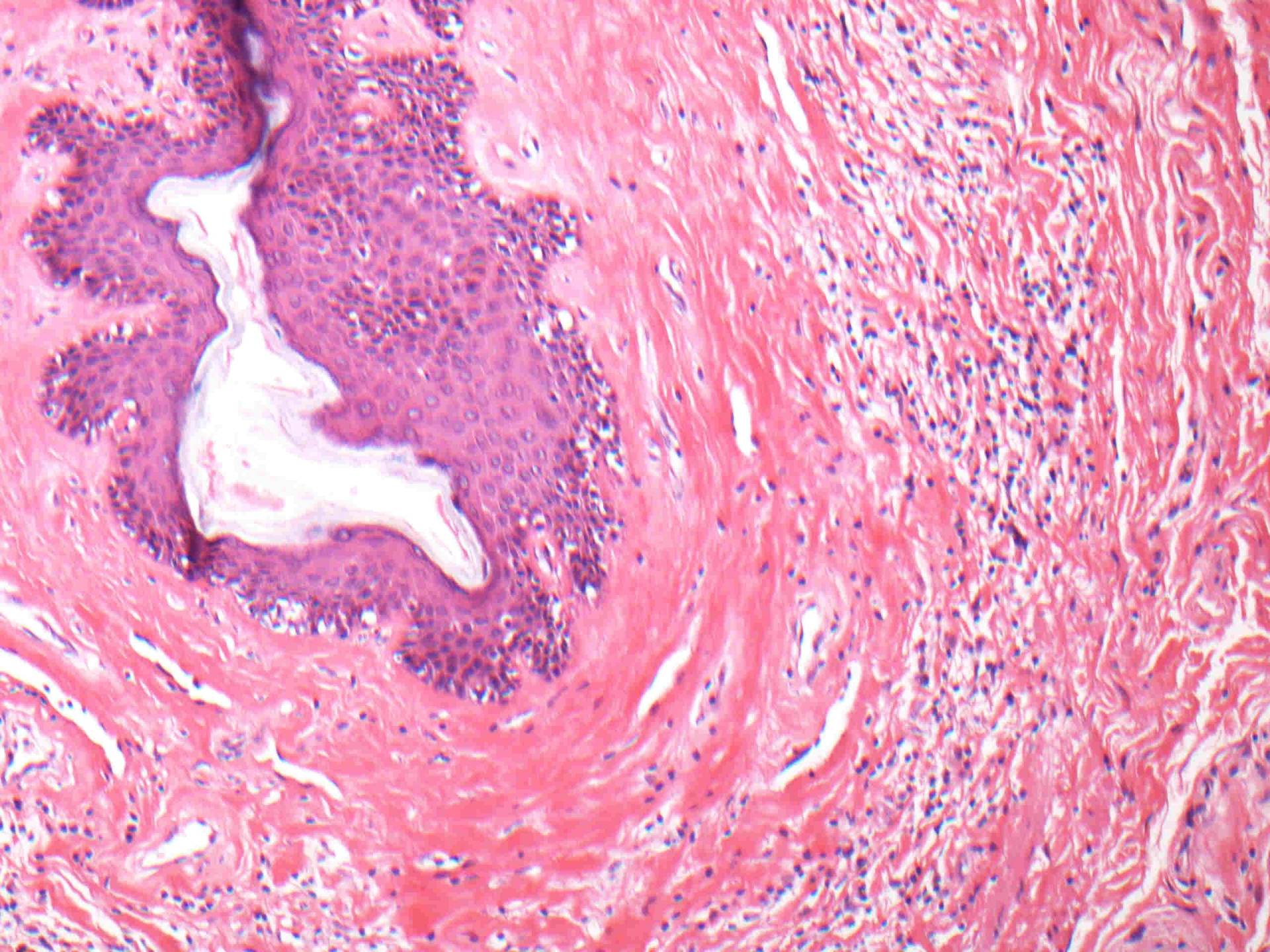
Case G – score 2 for discussion

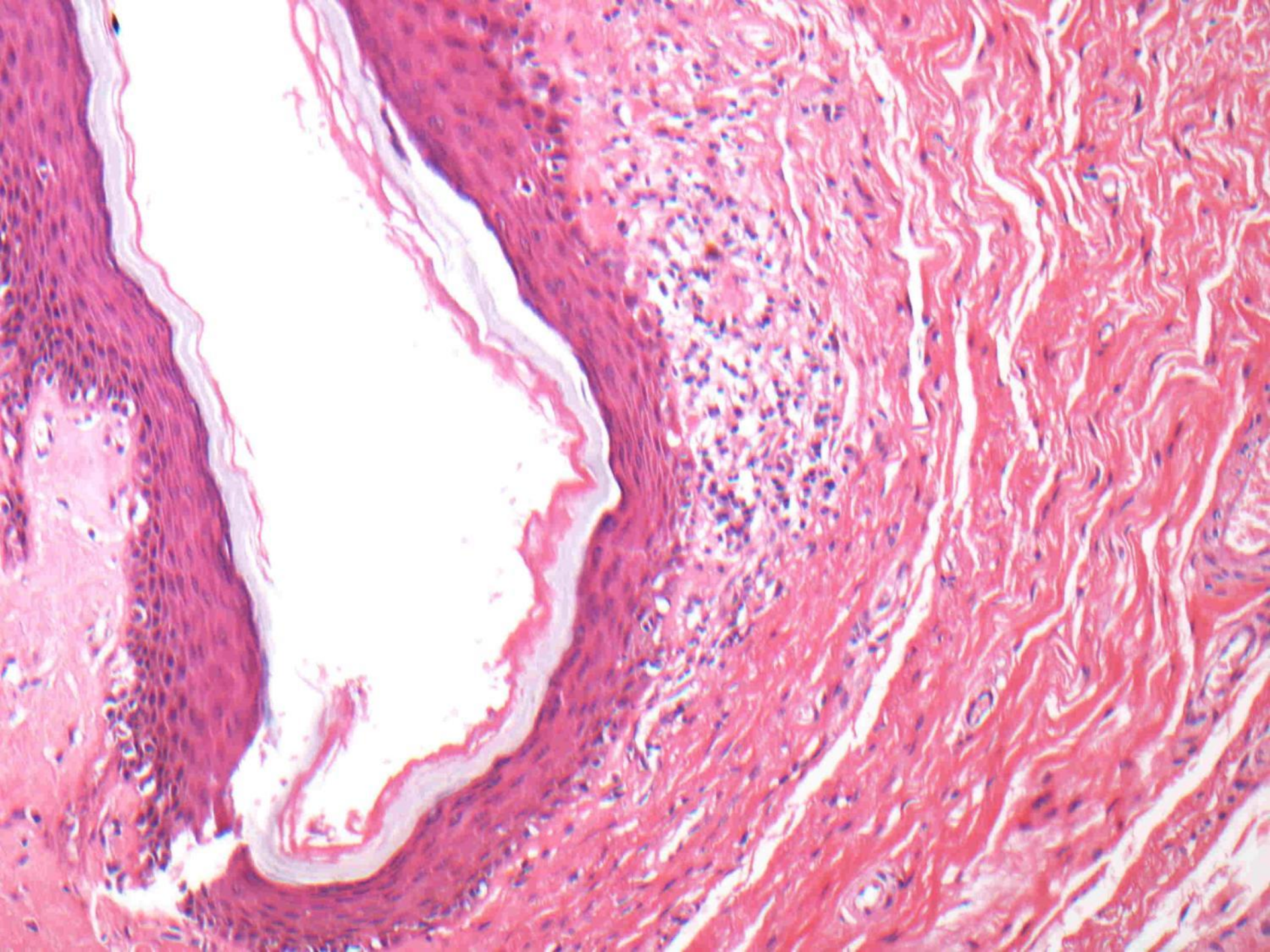
- Plexiform leiomyoma
- Fibroid
- Benign fibroid
- Hyaline degeneration of fibroid

Case H

- Male 47
- Circumcision for phimosis







Case H – Lichen sclerosus

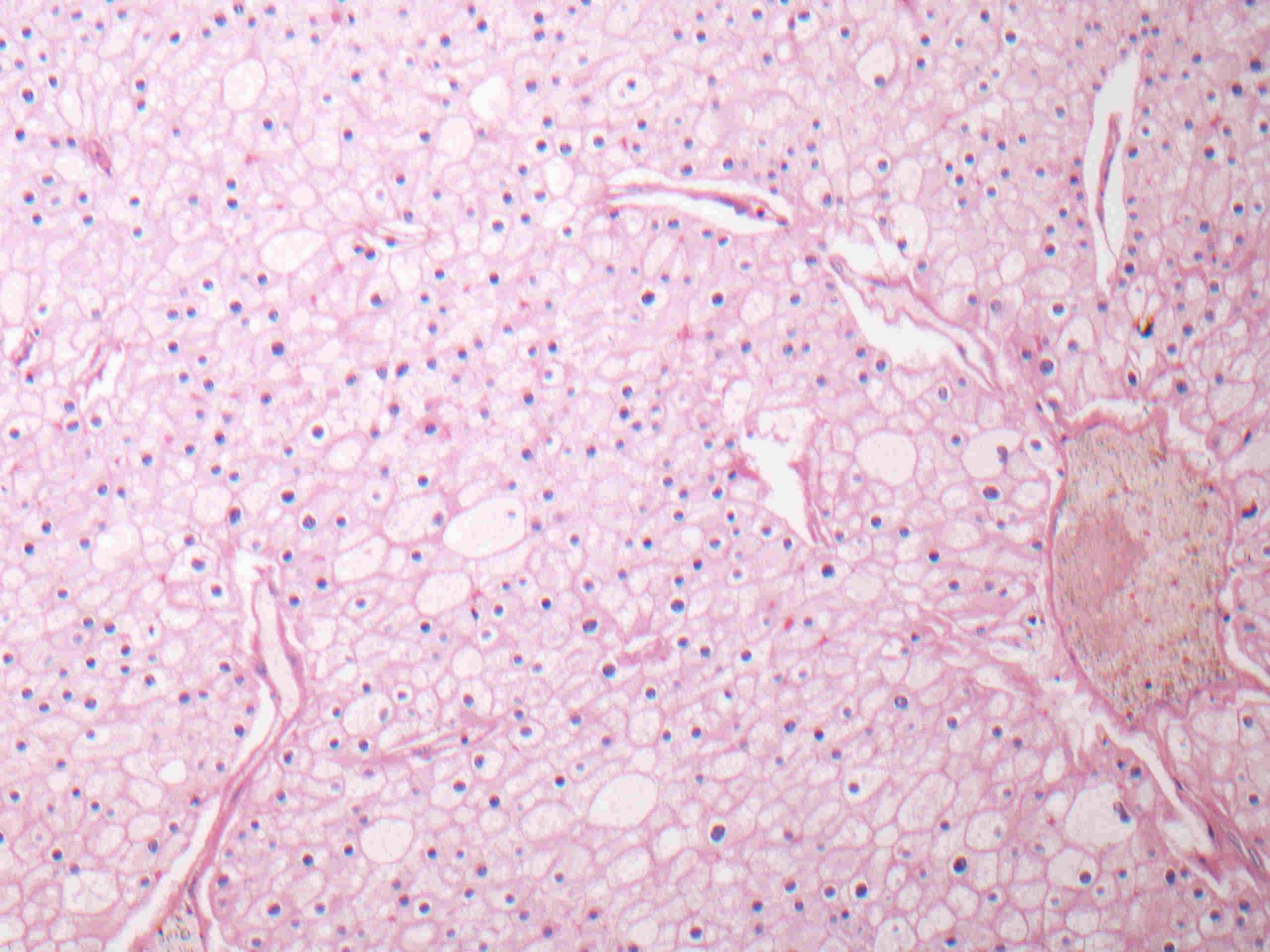
- 124 responses
- All score 1

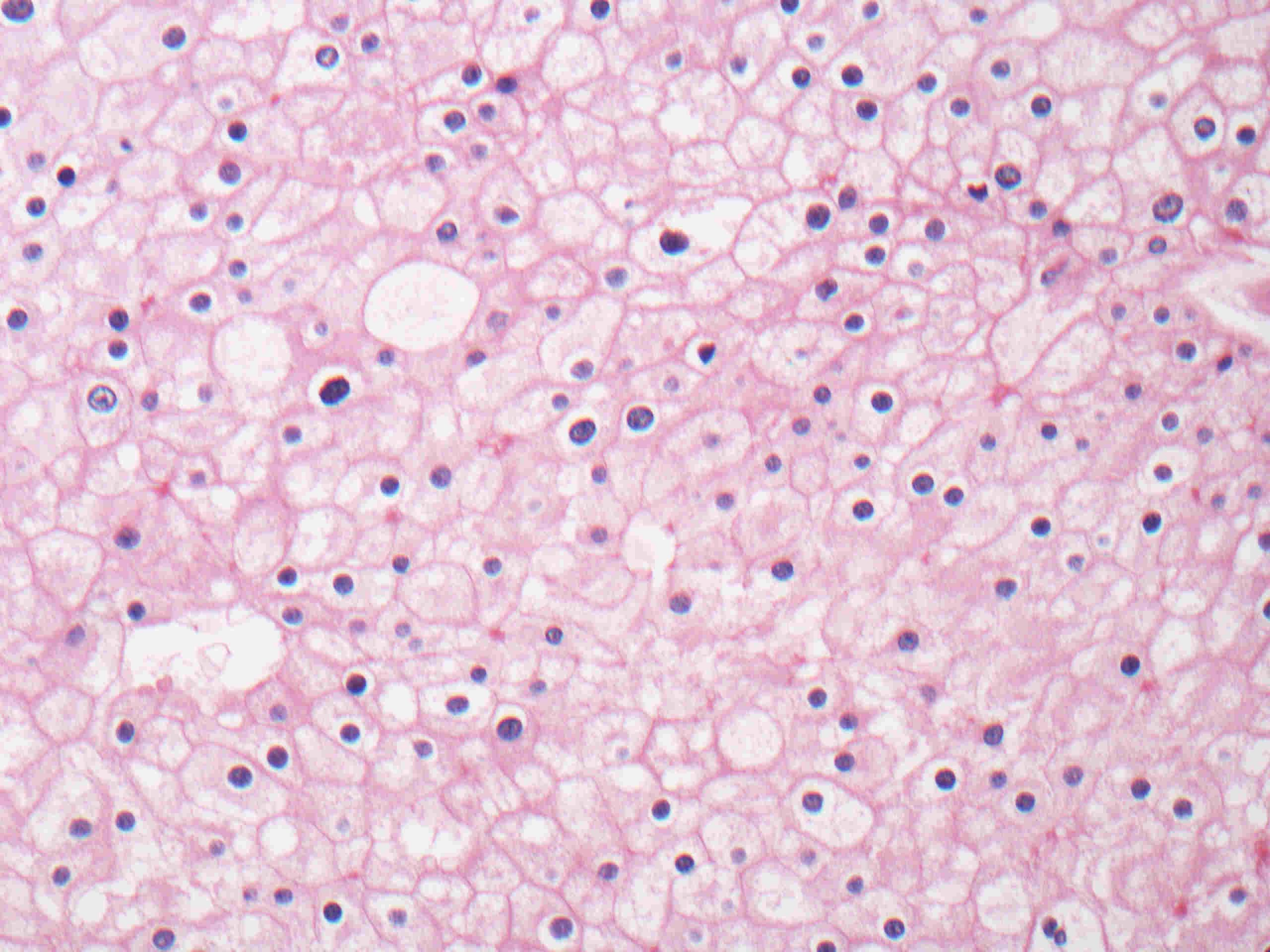
Case H – score 1

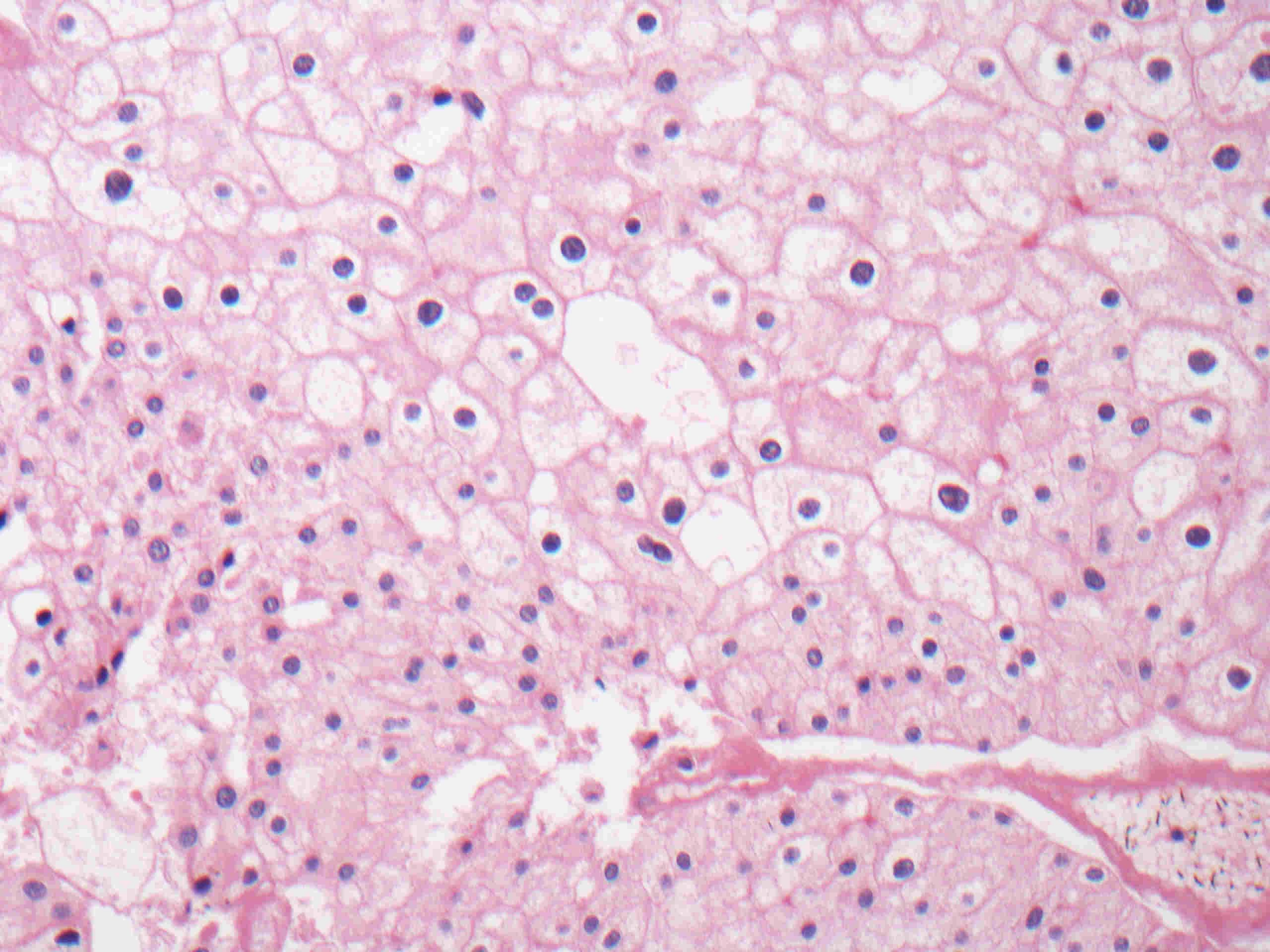
- Balanitis xerotica obliterans
- Posthitis xerotica obliterans
- Lichen sclerosus

Case I

- Male 85
- Incidental renal tumour







Case I – Chromophobe renal cell carcinoma

- 124 responses
- Score 1 – 108
- Score 2 - 16

Case I – score 1

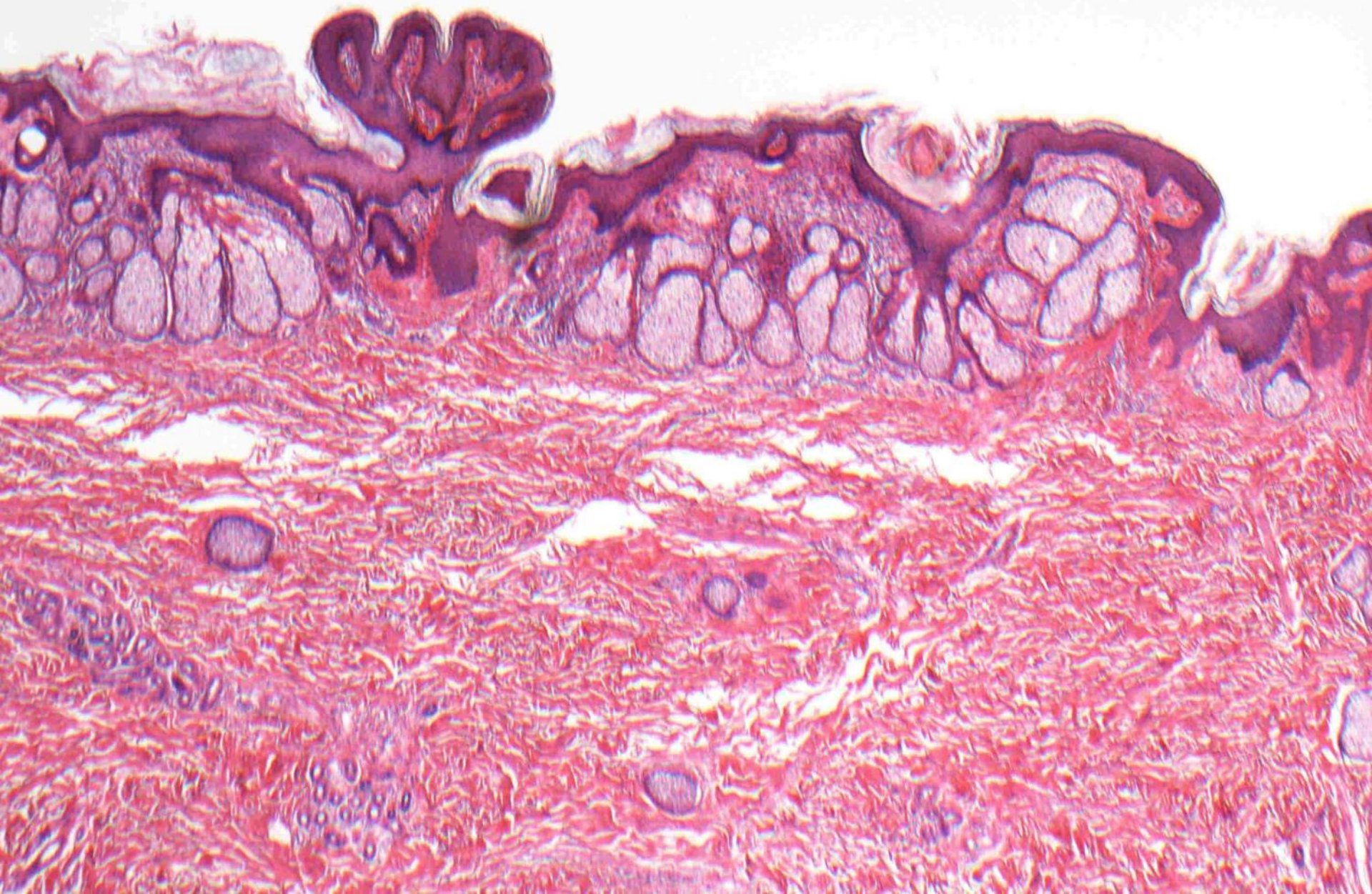
- Chromophobe renal cell carcinoma

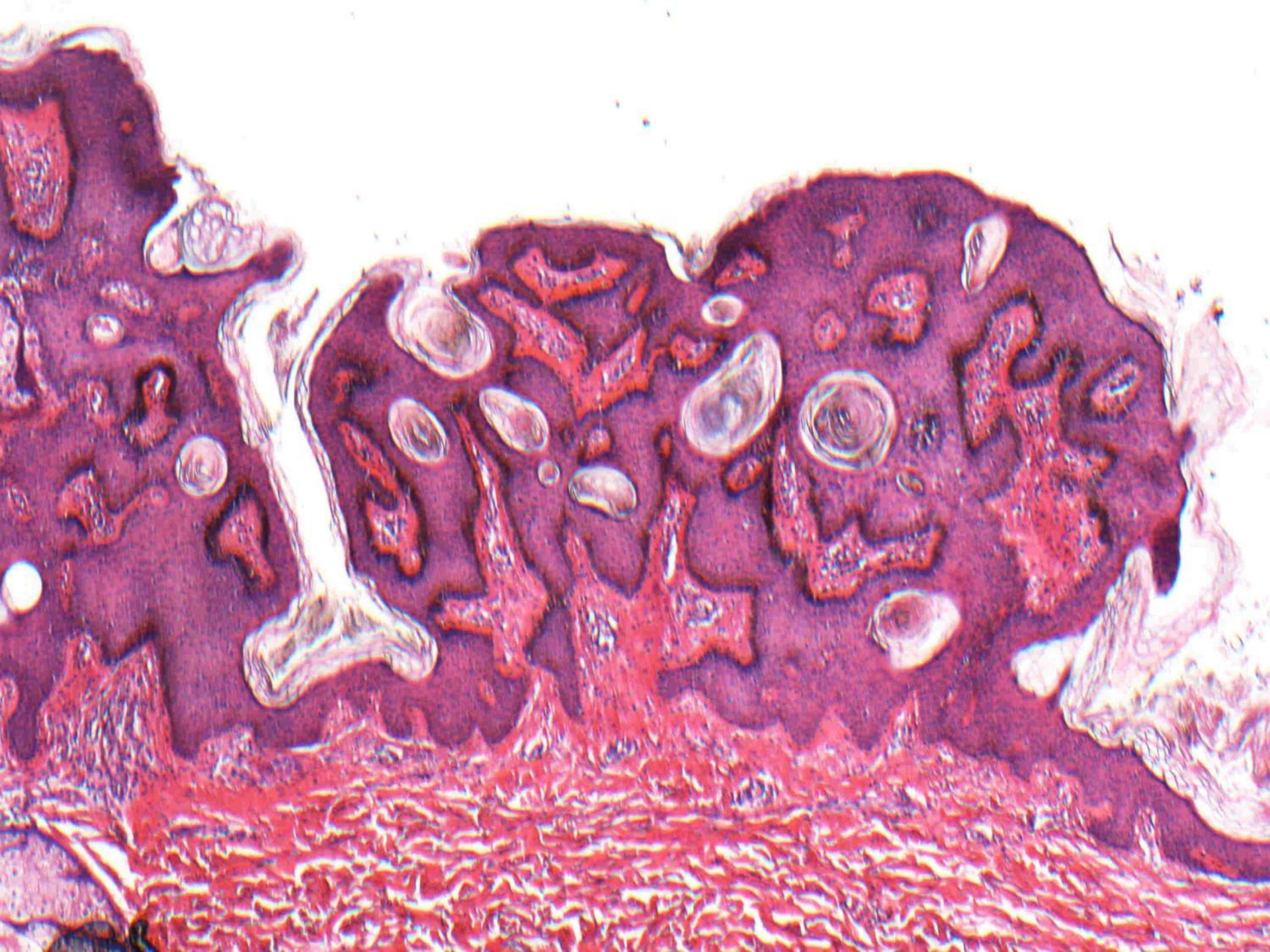Case 1 – score 2 for discussion

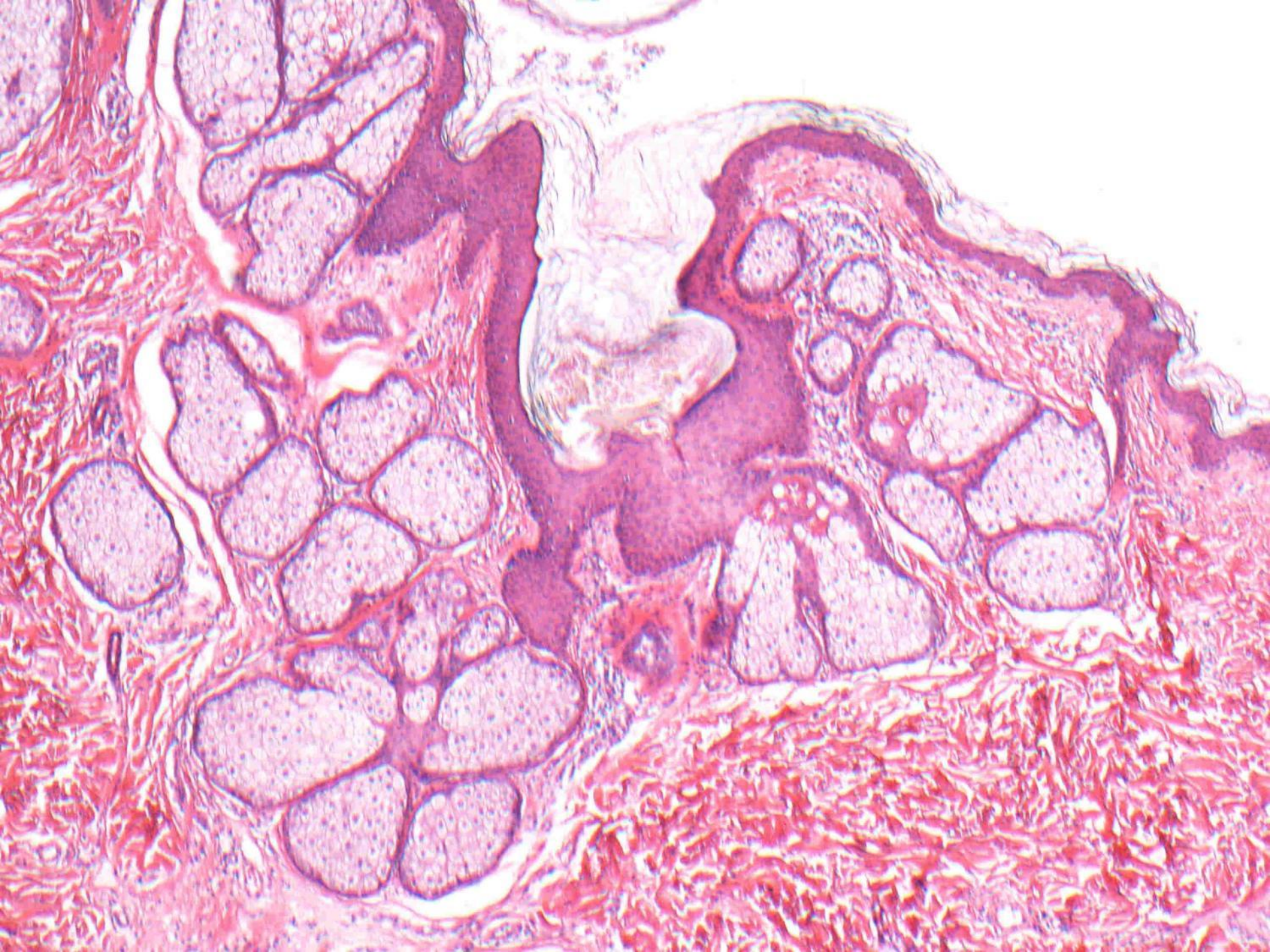
- Renal cell carcinoma NOS x 3
- Clear cell renal cell carcinoma x 11
- Eosinophilic variant of clear cell RCC x 2

Case J

- Female 25
- Flattened warty lesion on back
- Present since birth







Case J – Sebaceous naevus

- 124 responses
- Score 1 – 121
- Score 2 – 2
- Score 3 - 1

Case J – score 1

- Sebaceous naevus/nevus/of Jadassohn
- Organoid naevus

Case J – score 2 for discussion

- Nevus lipomatosis
- Epidermal naevus
- Organoid epidermal naevus

- (Sebaceous hyperplasia – trainee)

Case J – score 3

- No answer given